IR Pathway

Learn The Right Way



Notes

Dr. Islam Elhelf, MD, PhD

Interventional Radiology

www.youtube.com/IRPathway

www.facebook.com/irpathway

www.instagram.com/.irpathway



Acknowledgment

"IR Pathway" acknowledges the valuable voluntary contributions of **Dr. Ahmed Atef**, Editor of the IR Pathway Companion Notes. We sincerely appreciate his dedication and commitment to producing high-quality educational material in support of the "IR Pathway" educational mission.

Dr. Islam Elhelf, MD, PhD

Founder - IR Pathway

Islam Elhelf



Episode 1: Vascular Access - Part 1

🧠 Core Principle in IR

- **Mastering the Basics** is essential before advancing to complex procedures.
- Interventional Radiology (IR) divides into two main categories:
  - **Vascular Interventions**: Procedures via blood vessels (arteries, veins, lymphatics).
  - **Percutaneous Interventions**: Procedures done through the skin (e.g., biopsy, ablation).

🩸 Vascular Interventions Overview

✅ Types of Vascular Access

- **Arterial Access**: For angiograms, embolization, etc.
- **Venous Access**: For thrombectomy, venous stenting.
- **Lymphatic Access**: For lymphangiograms, lymphatic embolization.

🧰 The IR Toolkit – From Evolution to Practice

📌 Essential Tools

1. **Guide Wire** – Steerable wire to navigate vessels.
2. **Catheter** – Tube passed over the wire for contrast injection or device delivery.

📈 IR Evolution Timeline

- **1950s–60s**: Introduction of **0.035" guide wire**
- **French (Fr) Scale** for catheter diameter:
  - 1 Fr = 0.33 mm
  - 4 Fr = 1.32 mm → Used with 0.035" wire
- **Gauge (G) Scale** for needles:
  - Higher G = Smaller size (e.g., 21G is smaller than 18G)

🧬 System Categories

System	Wire Size	Needle	Catheter Size	Use Case
Base / Macro	0.035"	18G	4 Fr	Support, Proximal Access
Micro	0.018"	21G/22G	2.0–2.8 Fr	Distal navigation, Safer, Less trauma

✅ System Pros and Cons

🔷 Micro System (0.018"/21G)

- **Pros**:
  - Safer access
  - Better navigation to distal vessels
- **Cons**:

- Soft, limited support
- Not suitable for high-caliber interventions

🔷 Base/Macro System (0.035"/18G)

- **Pros**:
  - Strong support
  - Suitable for proximal vessel navigation
- **Cons**:
  - Larger arterial puncture
  - Higher bleeding/dissection risk

🔄 Why Switch Between Systems?

- Start with **micro-system** for safe access.
- **Switch to macro-system** for stability & intervention.
- This is why operators change tools frequently — it's all about **matching tool size to task.**

💡 Understanding Vascular Access

🩺 Primitive Method

- Direct needle access → Not suitable for repeated tool changes → Risk of hematomas.

🧠 Seldinger Technique (1953)

- Access vessel with needle → Insert guide wire → Remove needle → Maintain access.
- Originally done via **palpation**, later improved by:
  1. **Ultrasound-guided access**

2. **Micro-system usage (21G needle, 0.018" wire)**

🛠️ Tool Highlight: Micro Puncture Kit

- Components:
  1. **21G Needle**
  2. **0.018" Wire**
  3. **4 Fr Outer Sheath** + **Inner Dilator** (for 0.018" wire)

🔁 Switching from Micro to Macro System

1. Access with micro-system.
2. Insert 0.018" wire → Remove needle.
3. Advance dilator+sheath over wire.
4. Remove 0.018" wire + dilator.
5. Insert **0.035" wire** → You're now in **macro system**.
6. Ready to advance a sheath or catheter over the 0.035" wire.

❓ Why Not Stay with Micro System?

- Micro wire is too soft to support sheath/catheter advancement.
- Macro wire is stiffer, ideal for tool delivery.

📌 Final Concept Summary

- **Start Small, Switch Smart**: Begin with micro for safety → switch to macro for support.
- Understanding this explains IR workflow & catheter changes in procedures.
- Choose system based on:
  - **Safety**
  - **Anatomy**

- **Intervention type**
- **Tool compatibility**



Episode 2: Vascular Access - Part 2

🧠 Introduction to Sheaths in Interventional Radiology

- **Why Not Just Use a Catheter?**
  - Catheters can be introduced directly over a guide wire, but:
    - **Larger Opening**: The catheter has a larger outer diameter, making the hole bigger than the guide wire. This can cause bleeding upon removal.
    - **Lack of Stabilization**: Without a sheath, the guide wire can shift, leading to loss of access into the vessel.
- **Why we need a vascular sheath?**
  - **Prevents Bleeding**: By ensuring that the catheter doesn’t cause unnecessary bleeding when inserted or removed.
  - **Stabilizes Access**: Maintains access throughout the procedure.
  - **Supports Multiple Catheters**: Provides a stable port for switching between multiple catheters during a procedure.

🩸 The Sheath: Key Features and Functions

1. **Sheath Structure**
    - **Components**:
        - **Dilator**: Prepares the path for the sheath and provides rigidity/ stiffness to prevent bending during insertion.
        - **Sheath Tube**: A short catheter with a valve that keeps blood from exiting, preventing bleeding. However, it allows easy introduction of catheters and wires.
        - **Side Arm**: Allows for saline flushing and contrast injection for vascular imaging.
2. **Functions of the Dilator**
    - **Dilation**: Expands the soft tissue track to accommodate the sheath.
    - **Rigidity**: Prevents the sheath from bending upon insertion.
    - **Tapered Tip**: Makes insertion easier by reducing resistance when entering the skin.

🛠️ How to Use a Sheath Properly

- **Step-by-Step Sheath Insertion**:
    1. **Flush**: Always flush with saline before use to remove manufacturing residues.
    2. **Insert Dilator**: Helps provide rigidity and aids the insertion of the sheath.
    3. **Ensure Proper Locking**: Make sure the dilator is locked in place with a "click" sound before insertion.
    4. **Insert Sheath**: Ensure the sheath is positioned correctly; use side arm for flushing and injecting contrast.
- **Valve Function**: Prevents blood leakage while allowing easy introduction of IR tools.

✅ Advantages of Using a Sheath

- **Prevents Hematoma**: Keeps access site sealed and reduces bleeding risk.
- **Continuous Access**: Maintains access to the vessel, even if the guide wire is accidentally removed.
- **Facilitates Catheter Insertion**: Tools can be advanced without disturbing the access point.

🔪 Sheath Sizes and Measurements

- **Sheath Sizing**: Measured by inner diameter (e.g., 5 Fr sheath corresponds to a 5 Fr catheter).
- **Color Coding System**:
  - **5 Fr**: Gray
  - **6 Fr**: Green
  - **4 Fr**: Red (used for pediatric interventions)
- **Length Variations**: Sheaths come in different lengths (e.g., 11 cm for vascular access, longer like 25 cm for more complex procedures).

🧬 Choosing the Right Sheath Based on Procedure

- **Long Sheaths**: Used when dealing with tortuous paths (e.g., atherosclerotic arteries), improving catheter torqueability.
  - **Example**: For patients with tortuous arteries, a longer sheath brings the control point closer, improving maneuverability.
  - **Application**: In liver biliary interventions or procedures requiring more control, longer sheaths provide better control and efficiency.
- **Torqueability**: Refers to the ability to transfer movement from the external hub of the catheter to the internal tip. Longer sheaths improve torqueability in tortuous pathways.

What is Torqueability?

- **Definition**: Torqueability refers to the ability of a catheter to transmit rotational movement from its external hub (the part controlled by the operator) to its internal tip (the part inside the patient's vessel).
- **Key Concept**: The greater the torqueability, the more effectively the operator can control the catheter tip's direction by rotating the external part.

Factors Affecting Torqueability

1. **Catheter Softness vs. Rigidity**:
    - **Softer Catheters**: Tend to have lower torqueability because their flexibility makes it harder to transfer precise movements from the external hub to the internal tip.
    - **Stiffer Catheters**: Offer better torqueability, but they are less flexible, which can be challenging in some procedures.
2. **Pathway Characteristics**:
    - **Straight Pathways**: When the vessel path is straight (as in a younger patient with healthy arteries), the catheter's movement is more efficiently translated from the hub to the tip.
    - **Tortuous Pathways**: In older patients with arterial atherosclerosis, the path can be winding or curved. This tortuosity reduces torqueability, as the movement of the hub may not fully translate to the tip.

How to Improve Torqueability

1. **Use of Longer Sheaths**:
    - **Why it Helps**: A long sheath can straighten the tortuous pathway, allowing for better movement of the catheter through the vessel.
    - **Application**: In cases of tortuous arteries, such as in elderly patients with atherosclerosis, using a long sheath brings the control point closer to the target site, thus improving torqueability and reducing the effort required to manipulate the catheter.

Practical Implications of Torqueability

- **Straight Path (Young Patient)**: Torqueability is higher, so a shorter sheath may be sufficient, and catheter movement is easily controlled.
- **Tortuous Path (Elderly or Diseased Arteries)**: A longer sheath becomes crucial for better control, as it minimizes the tortuosity and enhances the efficiency of catheter manipulation.

Torqueability in Procedure Choice

- **For Smooth Access**: Use shorter sheaths for young patients with minimal arterial tortuosity.
- **For Challenging Access**: Use longer sheaths for older patients or those with tortuous arteries to improve the control and precision of the procedure.

🔁 Key Takeaways

- **Sheath vs. Catheter**: Sheaths are used for stable vascular access and preventing blood loss, while catheters are inserted through sheaths to perform interventions.
- **Sheath Use in Practice**: Choose a sheath based on the patient's anatomy (e.g., atherosclerosis, age) and the required procedure.
- **Torqueability**: A long sheath ensures better control and precision, especially in tortuous vessels.

📚 Practical Insights

- **Customization**: Different companies design sheaths with slight variations (e.g., tapered tips, radiopaque markers), but the core function remains the same.
- **Personal Preference**: The choice of catheter and sheath often comes down to personal preferences and familiarity with specific brands and tools.



Episode 3: Vascular Access - Part 3

🚨1. Overview

After watching this episode you will learn about:

•How to use bony & angiographic landmarks for precise access
• Why the mid femoral head is the sweet spot
• Step-by-step palpation & ultrasound-guided vascular access techniques
• Advantages of ultrasound over blind sticks
• Complications from incorrect access angles
• Why never to advance a wire against resistance!
• The value of a solid "Groin Run"
• The importance of sheath flushing with saline

🦴2. Landmark Identification and Skin Marking

- **Step 1:** Identify the mid-femur level using a radiopaque marker (e.g., clamp).
- **Step 2:** Mark the skin over this level with a pen.
- **Rationale:**

- Ensures access is: **Good practice** ✅
  - Above the bifurcation.
  - Below the **inferior epigastric artery** (usually arises medially).
    - Mid-femur level falls within the “safe access zone”.

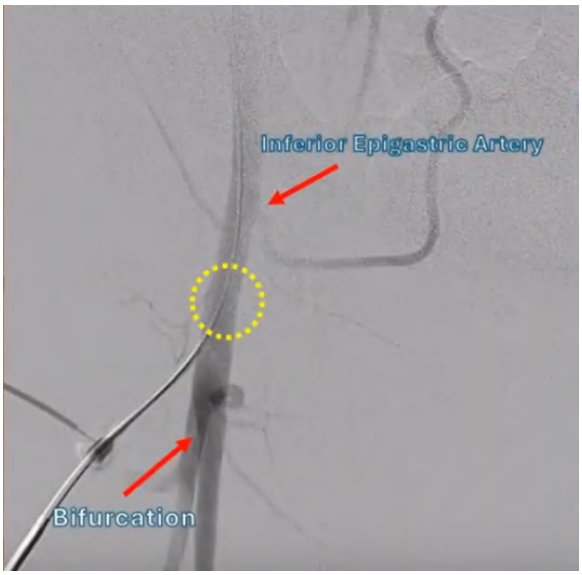

  - **Access Location Clarification:**
    - Level of mid-femoral head ≠ exact midpoint of femoral head.
    - Artery often slightly medial — still acceptable.

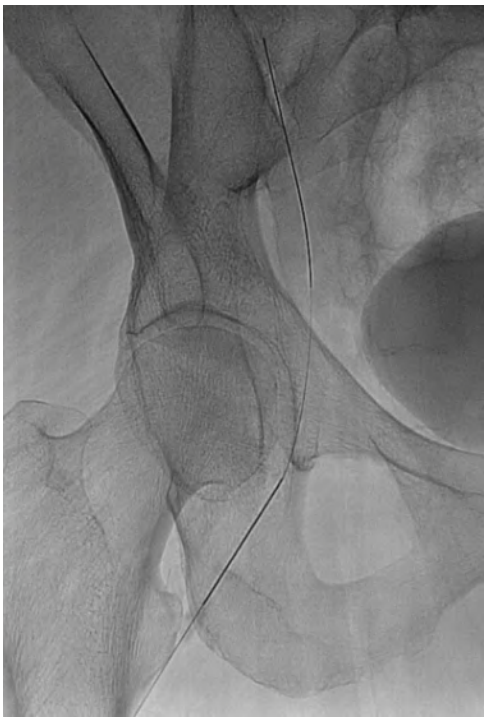

☑️3. Why Mid-Femur Level Is Ideal ?!

A. Anatomical & Technical Reasons Exam point ⚠️

1. **Above Bifurcation:**
    - Avoids puncturing small distal branches → prevents occlusion & ischemia.
2. **Artery-Vein Proximity:**
    - Lower levels → arteries & veins are closer → increased AVF risk specially when using palpation guided access.
    - Higher levels → better separation of arteries from veins.
3. **Compression Efficiency:**
    - Head of femur provides a firm surface for hemostasis via compression.
    - Especially important in obese patients.

🔑4. Access Techniques

A. Ultrasound (US)-Guided Access

- **Still mark mid-femur** to confirm US findings.
- **Advantages:**
  - Detects calcifications/atherosclerosis.
  - Prevents inaccurate puncture location.
- **Technique:** Good practice ✅
  - Transverse scan from caudal to cranial.
  - Find convergence of superficial and deep femoral arteries into CFA.
  - Avoid calcified segments.
  - Enter vessel at **45-degree angle**.

B. Palpation Method

- Use two or three fingers to identify the strongest pulse.
- Insert needle between two fingers at **45-degree angle**.
- Avoid puncturing through soft tissue where pulse is transmitted indirectly.

💉5. Puncture Technique

- **Angle:** Always insert at **45°**. Good practice ✅
  - Too steep → wire curves, difficult insertion. Bad practice 🚫
  - Too shallow → skin puncture far from arterial entry → higher arterial puncture causing ineffective post-procedure compression. Bad practice 🚫
- **Confirm Access:**
  - Blood return → insert wire → micro puncture set → fluoroscopic spot image.
  - Serves medico-legal purposes and confirms good access..

☢️6. Key IR Rule

- **Never advance a wire against resistance.** Good practice ✅ Exam point ⚠️
  - May lead to:
    - **Subintimal dissection** (especially with atherosclerosis).
    - Worsened outcomes during sheath insertion.
- **Red flags:** Bad practice 🚫
  - Wire resistance.
  - Buckled/looping wire = Stop and reevaluate.

🩻7. Fluoroscopic Confirmation

- Early training: frequent use of fluoroscopy to learn wire feel (make sure to apply radiation protection standards).
- Ensures:
  - Correct wire path.
  - Enough wire insertion to support sheath advancement.
  - Proper sheath placement.

🧲8. Sheath Insertion & Maintenance

- Insert 0.035″ wire → advance sheath → remove dilator.
- Aspirate & flush sheath: Good practice ✅
  - No continuous/ easy blood flow = possible complication.

🦴 9. Groin Run Good practice ✅

- **Contrast Injection** at sheath:
  - Confirms access quality.
  - Checks for flow obstruction (e.g., due to vasospasm or sheath occlusion).

- Done early → timely management of problems (e.g., ischemia in sedated/trauma patients).

- **Imaging Tips:**
  - Slight oblique X-ray view opens bifurcation view.
  - Warn patients about warmth sensation from contrast.

📸10. Digital Subtraction Angiography (DSA)

- Purpose: Subtracts bone for better visualization of angiographic findings.
- Process:
  - Opacification → antegrade flow → complete contrast washout.
  - No contrast retention or blowout → confirms safe access.

🚰11. Continuous Flushing Good practice ✅

- **Crucial Step:**
  - Prevents clot formation inside sheath.
- **Saline Bag Under Pressure:**
  - Prevents blood reflux into the sheath side arm.
  - Pressure adjusted using cuff (similar to BP cuff) to maintain continous forward saline flow through the sheath.



Episode 4: Complications of vascular access - Part 1

- Focus: **Predisposing factors for complications, Pseudoaneurysm (PSA)** & **Dissection**
- Builds on prior knowledge of **tools + techniques**

⚠️ Predisposing Factors → Risk of Complications

🧬 Coagulopathy / Anticoagulation

- 🚩 *Top risk factor*
- Elective → stop anticoagulants per **SIR guidelines** Exam point ⚠️
- Emergency → no time to correct (e.g., INR 3.2, Plt 15k → high risk even if you give FFP) Good practice ✅

⚖️ Obesity

- ↓ Compression efficacy due to thick **subcutaneous fat**
- ↑ Risk if puncture is high
- *Ideal puncture = mid femoral head level*

💀 Renal Failure

- ➤ *Platelet dysfunction* even with normal count (e.g., 75k acts like 15k) **Exam point** ⚠️
- ➤ *Vascular calcifications* → access becomes harder

🔪 Sheath Size

- ↑ Sheath size → ↑ Bleeding risk

  → e.g., **7 Fr > 5 Fr > 4 Fr**

💥 Pseudoaneurysm (PSA)

📌 What Is It? Exam point ⚠️

- **Hematoma** → Blood collection *not* communicating with artery
- **PSA** → Blood collection *with* arterial communication via a **neck**

  → Wall = fibrous tissue (*no true layers*)
- **True Aneurysm** → Involves **intima + media + adventitia**

🔍 PSA Diagnosis Good practice ✅

1️⃣ After the Procedure

- Pt returns with *pulsatile groin mass*
- Incidental finding on CTA → *Contrast-filled sac near artery*

2️⃣ During the Procedure

- Sudden groin swelling after sheath removal
- **Ultrasound** → Classic "yin-yang" flow pattern **Exam point** ⚠️

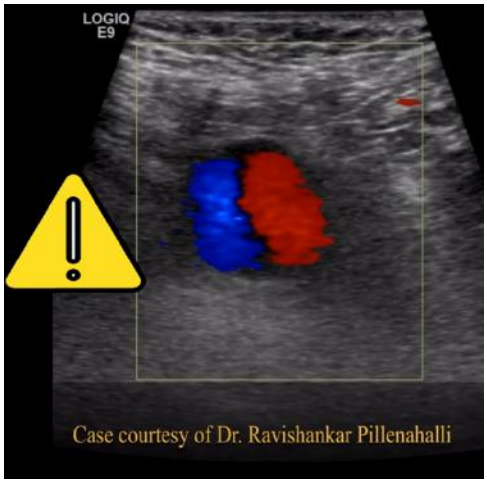

- **Angiography** → Contrast *leak* from artery



- **CTA** → Enhancing collection connected to artery

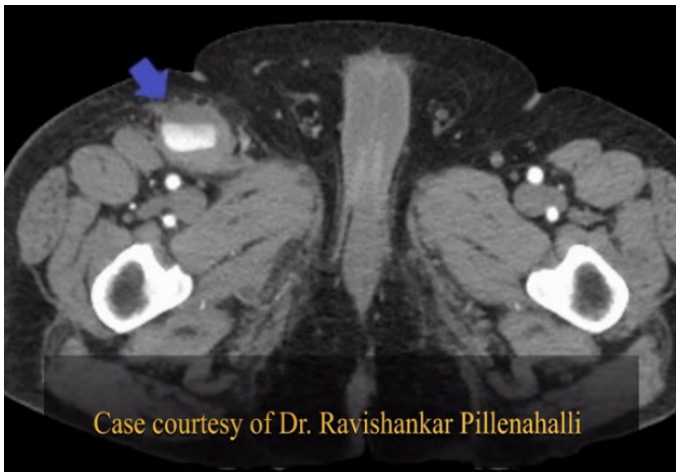

- Note: PSA may result from prior *failed access attempts* (not always current)

🛠️ PSA Management

✅ Conservative

- For small (<3 cm) → May resolve spontaneously

  → Weekly Doppler → Usually closes in **3–4 weeks** Exam point ⚠️

🌀 US-Guided Compression

- Press **directly on PSA neck**

  → Goal = **thrombosis & neck closure**

  → Avoid parent artery compression

  → Watch for disappearance of **yin-yang flow**

💉 US-Guided Thrombin Injection

- Inject **thrombin into PSA sac** → induces clot
- ⚠️ Avoid leak into artery → may cause arterial thrombosis and occlusion Bad practice 🚫
  - 🧠 *Tips*:
    - ✅ *Small neck* → less risk of thrombin leakage Exam point ⚠️
    - ✅ Inject *away from neck* Good practice ✅

- 🔻 Even partial thrombosis (e.g., 85%) → often enough

🧬 Covered Stent

- Used when:
  - 🛑 Wide neck
  - 🛑 Failed thrombin/compression
- Stent graft isolates PSA from circulation

  → Blood flows through stent leading to PSA thromboses
- Recommend expert consultation or vascular referral if inexperienced

🔪 Surgery

- Last resort
- Indicated if: **Good practice** ✅
  - Vascular or neurological Compression symptoms
  - Rapid expansion or ischemia

    → Artery is repaired or patched surgically

🧩 Arterial Dissection

📘 Definition

- Tear in **intima** → Wire tracks into **subintimal plane** (wrong path)

🧬 Risk Factors

- Elderly → *Severe atherosclerosis*
- Renal failure → *Vascular calcifications*
- Operator error → *Advancing wire against resistance*

🧪 Dissection Detection

🩸 Clinical Clue

- Sheath aspiration → *poor or interrupted flow* instead of normal arterial jet
  Good practice ✅

📽️ Angiographic Signs **Exam point** ⚠️

- Contrast is retained in false lumen → *slow clearance*
- Intimal flap → thin radiolucent line
- Note: May stem from *previous* access attempts

Ask yourself:

- Is this dissection **flow-limiting** (interfering with distal blood flow**)**?
  - If not ➤ conservative management may suffice
  - If yes ➤ intervention required

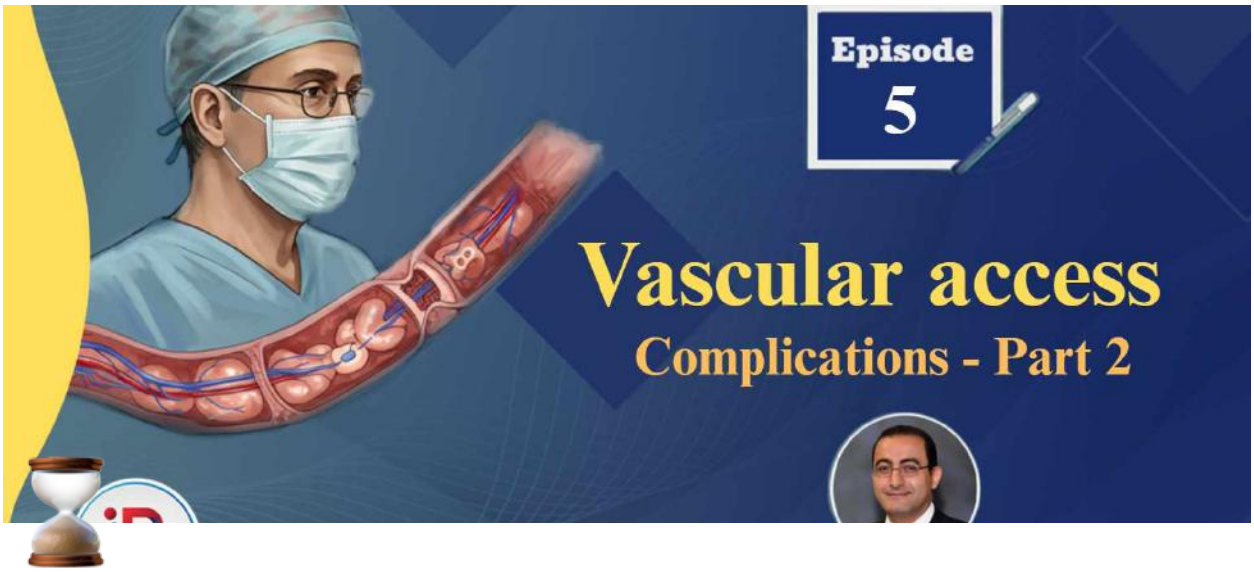

Episode 5: Complications of vascular access - Part 2

1️⃣ Dissection

🩻 What?

Tear in intimal arterial wall → may/may not affect flow.

🔷 Non-Flow-Limiting

- ✅ Small tear → **no distal flow issue**
- 🛠️ Conservative:
  - ✔️ No intervention needed (heals spontaneously) Good practice ✅
  - ✔️ Check **distal pulses** (dorsalis pedis, posterior tibial)
  - ✔️ Document with **ultrasound**
  - ✔️ Educate on symptoms: **color change, numbness, pain**
  - 🔁 Follow-up: Day 3 → 1 week → until healed

🔷 Flow-Limiting

- ❌ Affects distal blood flow → risk of **limb ischemia**
- 🛠️ Try to reverse:
  - ➡️ **Contralateral access** Good practice ✅
  - 🎈 **Balloon angioplasty** → flap reposition
    - Inflate for about 30 sec–1 min
    - Repeat angiogram after
    - Make sure wire is **intraluminal**, not in flap! Bad practice 🚫
- ❗ If failed:
  - 🧵 **Covered stent** → push flap to wall, restore lumen
  - 🔪 Last resort: **vascular surgery**

2️⃣ Arteriovenous Fistula (AVF)

🩻 **What?**

Abnormal connection: **artery** ↔️ **vein**

🔷 Causes

- **Low puncture site** (near branches) Exam point ⚠️
- Repeated or large needle punctures (e.g., 18G)

🔷 Detection

- During angiography: **vein fills during arterial phase** (abnormal) Good practice ✅

🔷 Management

- ✅ Small AVF: usually **closes spontaneously**
- 🔁 Follow-up: US + Doppler
- ❌ If symptomatic/persistent: Good practice ✅
  - Symptoms: swelling, blue leg (**steal phenomenon**) Exam point ⚠️

- Compression under US guidance
- Covered stent → isolate the connection
- Surgery if stent fails or complications occur

3️⃣ Thrombosis / Embolism / Ischemia

🫁 **What?**

→ Sudden artery blockage

→ Risk: **limb ischemia**

🔷 Causes

- **Unflushed syringe** → clot injection (Inspect the syringe before injection) **Good practice** ✅
- Plaque dislodgement → embolism
- No continuous flush **Bad practice** 🚫 → sheath thrombosis

🔷 Presentation

- **Filling defect** = floating clot

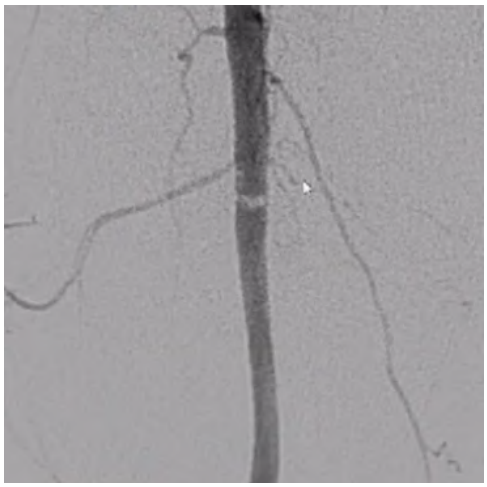

- **Abrupt cutoff** = complete occlusion

🔷 Management (Immediate)

- 🧲 **Aspiration thrombectomy**
  - Device (e.g., Penumbra or Inari) or wide-bore catheter (7 Fr)
- 🧪 **TPA thrombolysis** if aspiration platforms not available Good practice ✅
  - ✅ Fresh clot → good response Exam point ⚠️
  - ❗ Requires ICU + vascular surgeon Good practice ✅
  - ⚠️ Bleeding risk, monitor overnight
- 🔪 **Surgical thrombectomy**
  - If TPA not an option

4️⃣ Retroperitoneal Hematoma

🩻 **What?**

Major bleeding into pelvis/abdomen → dangerous!

🔷 Risk Factor

- 🔼 **High puncture** (above CFA bifurcation) Exam point ⚠️

🔷 Signs

- Delayed: **groin pain, swelling**
- Persistent **hypotension**, unexplained ↓ Hgb/Hct Good practice ✅
- Diagnosis: **CT/CTA** → hematoma ± active bleed

🔷 Management

🟢 Stable Good practice ✅

- 🏥 ICU monitoring
- 💧 Fluids + blood transfusion
- Correct coagulopathy: Exam point ⚠️
  - High INR → FFP

- Low PLT → Platelet transfusion
- On anticoagulants → reversal agents

🔴 Unstable / Fails Conservative

- 🚑 Transfer to IR suite if: **Good practice** ✅
  - Persistent hypotension despite treatment
  - ≥4 units blood in 24h
  - Starts vasopressors
  - ❌ Inappropriate transfusion response: For each one unit of pRBCs transfusion we expect about one point increase in Hb and 3 points increase in Hct. If this is not acheived despite transfusion it raises concern for active bleeding somwhere.
- 🔧 IR Interventions:
  - Angiogram
  - Coil or Gelfoam (small branch bleed)
  - Covered stent (CFA defect)
  - Continuous communication with ICU + vascular surgery
- 🚨 If rapidly worsening:
  - ⚠️ Risk of **abdominal compartment syndrome due to rapidly expanding retroperitoneal hematoma**
  - Skip IR → **Emergency surgery**



Episode 6: The First Interventional Radiology Rotation

The Four Pillars of Evaluation in an IR Rotation

From the perspective of a supervising consultant, residents on their first IR rotation are evaluated on four primary competencies. These are ranked not by importance, but by the level of resident anxiety versus the ease with which they can be managed.

1. **Communication Skills**
2. **Management Skills**
3. **Presentation Skills**
4. **Medical Knowledge**

This document will explore each of these pillars in detail, focusing on the practical steps and expectations for achieving excellence.

1. Communication Skills

The level of communication required in IR is significantly higher than in diagnostic radiology. Excellence in this area is a primary determinant of a resident's performance and evaluation. Communication can be divided into two critical categories: interaction with the internal IR team and interaction with external referring services.

Communication with the IR Team

The nurses and technicians within the IR unit are described as the "right & left hands" of the practice, without whom the work cannot function properly. Building a strong, professional relationship with this team is essential.

- **Maintain Professionalism:** All interactions should be conducted with mutual respect and a professional demeanor, always prioritizing the patient's best interest. This helps navigate interactions with various personality types.
- **Know Your Team:** It is unacceptable to be unable to recall a team member's name. Addressing colleagues by name shows respect and enhances professionalism.
- **Keep Contact Information Accessible:** A resident must have the phone or pager numbers for all team members readily available. This is crucial for urgent communications, such as relaying a last-minute request from a consultant about a specific tool or confirming a medication is ready for a morning procedure.

Communication with Referring Services

Unlike in diagnostic radiology where interactions can be one-sided, IR requires a relationship of mutual interest and cooperation with referring physicians.

- **Build a Professional Network:** When receiving a consultation, a resident should make it a habit to introduce themselves and obtain the name and contact information (phone or pager) of the referring individual. Within a few weeks, this practice creates a valuable list of contacts across different specialties.
- **Understand Mutual Dependency:** A good relationship with referring services is critical. For example, a chest physician who needs a CT read may be the same person a resident needs to contact for assistance if a patient develops a

pneumothorax during a lung biopsy. Good rapport facilitates smoother patient management.

- **Leverage Your Network:** The created contact list becomes a practical tool for solving problems quickly. Needing an urgent anesthesia consult, for example, is made easier when there is an established professional relationship with an anesthesiologist.

2. Management Skills: Mastering the Workflow

Management skills in this context refer to the resident's ability to manage the operational workflow of the IR unit. While the consultant is responsible for clinical decisions, the resident is responsible for the flow of work, presenting a significant opportunity to demonstrate competence.

Understanding and Documenting the Workflow

- **Be Proactive:** A resident should arrive at the unit a day or two before the official start of the rotation, especially if there is no senior resident overlap. This time should be used to meet the outgoing resident and learn the specific workflow.
- **Learn the System:** Key processes to understand include:
  - The initial step after receiving a new consult.
  - Where consults are placed for review.
  - The process for approved consults moving to the next stage.
  - The location and process for consults that require more information.
- **Document for Your Successor:** A recommended practice is for the outgoing resident to write down the unit's workflow in a clear, simple format to serve as a guide for the incoming resident, preventing them from having to "start from zero."

Systematic Information Gathering for Consults

A structured approach to collecting patient information is fundamental to managing cases effectively. The following data points must be gathered for every consult before presentation.

- **Basic Information:**
  - Patient Name and Medical Record Number (MRN).
  - Referring Service.
  - Contact information for the referring resident.
- **Clinical Details:**
  - **Reason for Consult:** The specific request (e.g., biopsy, drain placement, tumor ablation).
  - **Focused Medical History:** Relevant history related to the procedure. For a biliary drain consult in a patient with pancreatic cancer, it is critical to know that an endoscopic attempt by GI failed, but it is less critical to know about a knee replacement from 10 years prior.
  - **Allergies:** Specifically note any allergy to contrast media, which would necessitate premedication if contrast is to be used.
  - **Medications:** Identify any relevant medications, especially anticoagulants (e.g., heparin, warfarin, Plavix/clopidogrel). **A resident must never decide to stop these medications independently.** This decision requires a thorough discussion between the IR consultant and the referring team.
- **Essential Lab Work:** Three labs are essential for almost every IR patient. If they are not available, they should be requested before the case is presented.

Lab Test	Guideline Threshold	Rationale
INR	< 1.5	Assess bleeding risk for invasive procedures.
Platelet Count	> 50,000 (50k)	Assess bleeding risk for invasive procedures.
Creatinine	Varies	Assess renal function, as contrast media is often used.

- **Potassium (K^+):** Abnormal potassium levels can be a concern for nursing staff, especially if moderate sedation is planned. Any significant deviation should be communicated to the nurse and consultant.
- **Procedure-Specific Labs:** Certain cases require additional labs (e.g., AFP and a full liver function panel for a suspected HCC ablation).

- **Imaging Review:**
    - It is "extremely important" to review the imaging personally. Relying solely on the report is insufficient and can lead to embarrassing errors, such as misidentifying the location of a tumor (e.g., consult states segment 6, but imaging shows segment 2). The procedural approach is directly determined by the imaging itself.
- **Consent:**
    - **Patient Mental State:** Determine if the patient is capable of giving informed consent.
    - **Informed Consent Details:** The discussion must include all available options, expected outcomes (palliative vs. curative), and all potential risks. Complications should be presented honestly without causing unnecessary fear. In extremely high-risk cases, a consent for death may be required from family.
    - **Surrogate Consenter:** If the patient cannot consent, identify the authorized person who can sign on their behalf and ensure they are available. It is critical to have their contact information in case consent needs to be obtained over the phone (with a witness, per protocol).

3. Presentation Skills: The Crown of Performance

After mastering communication and data gathering, presentation skill is what synthesizes this work and allows the consultant to make the correct decision. The presentation may occur one-on-one or during morning rounds.

The Three Resident Scenarios

To illustrate the impact of presentation, consider a case of a 70-year-old male with pancreatic head cancer referred for a biliary drain at 1 a.m.

- **Scenario A (Excellent Presentation - Stable Patient):** The resident presents the case clearly: 70-year-old male for biliary drain, known pancreatic cancer, failed GI attempt. Labs are good (INR 1.1, Platelets 105k), bilirubin is 10. The

patient is hemodynamically stable (BP 120/80, HR 80), afebrile, and not on vasopressors.

    - **Impact:** The clear, complete information allows the consultant to quickly determine the patient is stable and the procedure is not emergent.
    - **Decision:** "We approve the case. Keep the patient NPO (nothing by mouth) after midnight. We'll do the procedure tomorrow morning at 7 a.m."

- **Scenario B (Excellent Presentation - Unstable Patient):** The resident presents the same initial story but highlights critical changes. The labs are poor (INR 2.8, Platelets 25k). The patient was stable, but in the last hour became hypotensive (BP 90/50), tachycardic (HR 110), and was started on one vasopressor.
    - **Impact:** The presentation immediately signals biliary sepsis, a medical emergency. The data on coagulopathy is also clearly presented.
    - **Decision:** An urgent intervention is required. The consultant will order FFP and platelets and direct the team to come in immediately for an emergency drainage procedure around 2 or 3 a.m. The decision is completely different from Scenario A due to the quality of the information provided.
- **Scenario C (Poor Presentation - Unprepared Resident):** The resident is unsure of critical data. He *thinks* platelets are above 50k but isn't sure. He does not know the INR, the patient's blood pressure, heart rate, or whether the patient is on anticoagulants.
    - **Impact:** This resident has "a serious problem" and "significant gaps in his presentation skills." Even if the resident has excellent technical skills, this lack of preparation is difficult to justify. The consultant cannot make an informed decision. The only potential saving grace is if the resident has good communication skills and can quickly call the referring service to get the missing information.

The core lesson is that the resident's presentation directly shapes the consultant's decision-making process. Failing to gather and present critical details, as in Scenario C, can endanger the patient, who might "not survive until morning."

4. Medical Knowledge

Medical knowledge is ranked last not because it is unimportant, but because it is the easiest aspect for a new resident to manage.

- **Defined Roles:** The IR unit has a well-defined workflow where nurses, technologists, and consultants each have clear responsibilities. A new resident is not expected to make the final clinical decisions.
- **Incremental Learning:** A strong foundation of IR knowledge can be built easily over time. The recommended approach is to use an accessible IR textbook and read about a specific procedure (e.g., uterine fibroid embolization) the day before it is scheduled.
- **Sufficient Resources:** Following videos on educational channels (such as "IR Pathway") and using a comfortable, easy-to-understand textbook is considered "more than enough" for a first rotation.



Episode 7: **Soft tissue access**

✅ Percutaneous Soft Tissue Access: Principles and Techniques

Percutaneous soft tissue access = same logic as vascular access → gradual upsize from small → large system.

🔷 Start: 21G needle + .018" wire (less traumatic)

🔷 End: 18G needle + .035" wire (stable working system)

- A “Neff Set” or an “AccuStick” set is used to make the transition from the 0.018 system to the 0.035 system.

- Both sets have 3 main components: 1- Inner Stiffener 2- Inner dilator that accommodates the 0.018 wire 3- Outer 4Fr sheat

---

1️⃣ Foundational Concepts

Purpose: Create safe tract → organ with minimal trauma.

Common uses:

- PCNT → renal drainage
- PTBD → biliary Drainage

Crucial step = converting .018" → .035" system.

2️⃣ Procedural Workflow (PCN Example)

1️⃣ **Targeting:** Locate kidney with US/fluoro → mark site.

2️⃣ **Puncture:** Insert 21G trocar → reach collecting system.

3️⃣ **Confirm:** Remove inner trocar → urine flow → inject contrast (fluoroscopy). Good practice ✅

4️⃣ **.018" Wire:** Insert + advance into collecting system.

5️⃣ **Needle Out:** Withdraw needle over wire.

6️⃣ **Neff Set In:** Advance over wire (stiffener gives rigidity).

7️⃣ **Remove Stiffener:** Once deep into the renal tissue→ remove it → continue with sheath + dilator. Good practice ✅

8️⃣ **Sheath In:** Leave 4F sheath in place.

9️⃣ **Upsize:** Replace .018" with .035" wire.

🔟 **Working Tract:** Keep .035" in place.

1️⃣1️⃣ **Dilate Tract:** Use serial dilators to reach desired size. Good practice ✅

1️⃣2️⃣ **Drain Placement:** Insert final drainage catheter.

3️⃣ Instrumentation

Trocar Needle: (21G)

- Outer cannula + inner stylet.
- ✅ Rigid for deep puncture.
- ✅ Less trauma on entry.

Neff Set: (18G) Good practice ✅

Component	Function
Inner stiffener	Adds rigidity → cross fascia/muscle (remove early)
Inner dilator	Slides over .018" wire → initial dilation
Outer sheath (4F)	Creates stable tract → radiopaque tip

Neff Set VS Vascular Micropuncture Set:

Feature	**Neff Set (Soft Tissue Access)**	**Micropuncture Set (Vascular Access)**
Purpose	Deep organ access (e.g., kidney, liver)	Vessel access (e.g., femoral artery, vein)
Length	Long → reach deep targets	Short → superficial vessels
Stiffener	✅ Has metallic inner stiffener → cross fascia/muscle	❌ None (not needed for vessels)
Needle Type	21G trocar (solid inner stylet)	21G hollow micropuncture needle
Initial Wire	.018" microwire	.018" microwire
Outer Sheath	4F sheath (Long - radiopaque tip)	4F sheath (shorter)
Transition Function	Converts .018" → .035" system	Same function
Tissue Resistance	Designed for thick tissue	Minimal resistance

4️⃣ Critical Techniques & Best Practices

Wire Selection: Good practice ✅

Type	👍 Pros	👎 Cons	Use
Steel	Strong, stiff	Hard to fix kinks	More experienced users
Nitinol	Flexible, kink-resistant	Less stiff	🔷 Best for trainees

Fluoroscopy:

➡️ Always advance set under live fluoroscopy. Good practice ✅

➡️ Detect & correct wire kinks early.

Minimize Trauma:

- ❌ Don’t advance stiffener deep. **Bad practice** 🚫
- ✅ Use radiopaque markers.
- ⚠️ Gentle wire handling.

Overcoming Resistance:

➡️ Rotate or spin device while advancing → easier through dense tissue. **Good practice** ✅



Episode 8: Drains - Part 1

Percutaneous Drains in Interventional Radiology

1️⃣ Historical Evolution

1.1 Pre-IR Era

- Antibiotics first
- Open surgery if failed
- Large incision + straight surgical drain (sutured)

1.2 Percutaneous Era (1970s →)

- Imaging enabled safe percutanous access
- Continuous external drainage

Required advances:

➡️ Reliable retention mechanism

➡️ Adaptable drain designs

2️⃣ Drain Design & Retention

2.1 Pigtail Catheter 🌀

- Curled distal tip → anchors in cavity
- Locking string → maintains curl

Manufacturer examples:

- Argon (Skater™): twist-lock hub
- Cook: handle-based lock

2.2 Malecot Catheter

- Winged / fin-shaped tip
- Expands inside cavity for fixation

3️⃣ Types of Drains

3.1 Multipurpose / All-Purpose Drains (MPD / APD)

Used for:

- Abscesses/ collections anywhere
- Nephrostomy
- Biliary drainage

Includes: pigtail + Malecot designs

3.2 Internal-External Drains

Nephroureteral Stent (Urinary): Good practice ✅

- Loop in renal pelvis → shaft → loop in bladder
- External bag **or** capped → internal drainage

Internal-External Biliary Drain:

- Holes along the shaft down to the pigtail in the duodenum
- External drainage **or** capped → bile flows naturally

3.3 Internal Ureteric Stent (Double-J)

- Two curls: kidney + bladder
- Fully internal
- Placed retrograde (urology) or antegrade (IR)

3.4 Modified APD

Indication: multiloculated collections

- Standard pigtail drains only around the curled end
- Modification: extra side holes cut proximally ✂️

➡️ Drains multiple non-communicating pockets

4️⃣ Aspiration vs Drainage Good practice ✅

Factor	Aspiration	Drain
Size	< 3 cm	> 3 cm
Nature	Simple	Multiloculated
Fistula	❌	✅
Leak (bile/urine)	❌	✅

Key rule:

Fistula present → Do not **remove drain without surgery input** Exam point ⚠️

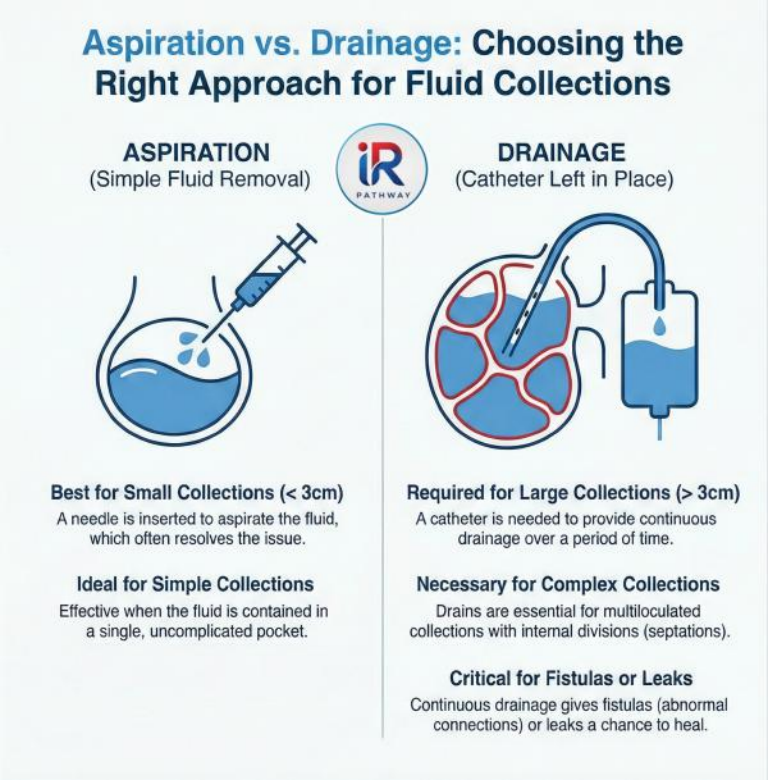

5️⃣ Pre-Procedure & Placement

5.1 Antibiotics 💉

Mandatory if: **Exam point** ⚠️

- Biliary obstruction
- Urinary obstruction

➡️ Give within **1 hour pre-procedure**

➡️ Prevent bacteremia and sepsis

5.2 Imaging Guidance

- **Ultrasound:** superficial, clear window, fast
- **CT:** deep collections, bowel nearby, narrow access

5.3 Placement Techniques

Seldinger:

Needle → wire → drain over wire

Trocar:

Drain + sharp stylet → direct puncture

No wire used



Episode 9: Drains - Part 2

1. Drain Basics (Skater / Pigtail Drain)

Components

- Drain catheter → pigtail tip → prevents internal dislodgement
- Plastic stiffener → routine support
- Metal stiffener → tough / fibrotic tissue
- Trocar → sharp needle for direct puncture

Preparation

- Drain comes **looped (pigtail)** → cannot insert as-is



- Insert stiffener → straightens drain → locks pigtail open



- Flush drain before insertion → ensure patency

---

2. Drain Insertion Techniques

A. Trocar Technique

What it is

- One-step **direct stick** technique

How

- Trocar → inside metal stiffener → inside drain
- Trocar tip protrudes ~0.5 cm beyond drain tip
- Single puncture → into collection

When to use

- Superficial collections
- No critical organs in path

Pigtail Placement Good practice ✅

- All pigtail **side holes must be inside collection**
  - Hole outside → fluid leaks outside the collection→ Failure and may cause problems
- Avoid excessive tightening of the string to avoid over looping of the drain Bad practice 🚫

Advantages of Trocar technique:

- Fast

- Simple

Disadvantages / Risks

- ++Traumatic
- High risk of surrounding bowel or organ injury if not identified correctly
- Not ideal for deep or complex collections

B. Seldinger Technique

What it is

- Multi-step **wire-guided** technique

How

1. Needle → access collection
2. Guidewire → passed into cavity
3. Needle removed
4. Tract dilated (if needed)
5. Drain + stiffener → advanced over wire

When to use

- Deep collections Good practice ✅
- Near bowel, vessels, liver, spleen

Advantages

- Precise
- Safer
- Preferred by IR

Disadvantages

- More steps

---

3. Drain Maintenance

Drainage System Choice Good practice ✅

Fluid Type	System	Why
Thick / pus / hematoma	Suction bulb	Pulls debris using continued negative suction
Bile / urine	Gravity bag	Continuous passive flow

Flushing vs Irrigation

Flushing Good practice ✅

- Inject 10 cc saline
- 1–2× daily
- Purpose → maintain patency

Irrigation (✖️ contraindicated) Bad practice 🚫

- Inject + aspirate
- Causes irritation of the cavity linning
- Can trigger bacteremia and possibly sepsis

Key Clinical Rule Bad practice 🚫

- Flushing should be **painless**
- Pain during flush → drain may be displaced → peritoneum

  → **Do drain check under fluoroscopy**

4. Monitoring Drain Function

Working Drain Good practice ✅

- Output gradually ↓ (50 → 20 → 10 cc)
- Fever ↓
- WBC ↓

Failing Drain

- Sudden output cessation= 0
- Patient still febrile / WBC ↑

  → Drain clogged or displaced

  → **CT evaluation may be needed to asses residual fluid collection**

5. Drain Removal Criteria

Remove only if BOTH are met

1. Output < 10 cc for 48 hrs
2. Patient clinically improving

---

6. Tract Maturation (CRITICAL CONCEPT) Good practice ✅

Why it matters

- Immature tract → internal leak → peritonitis

Time Required

- External abscess → 2–7 days
- Nephrostomy → 10–14 days
- Biliary / cholecystostomy → **3–4 weeks (minimum)**

---

7. Safe Drain Removal Steps

Never pull a locked pigtail

Steps

1. Release locking string

   → usually cut proximal drain
2. Pigtail straightens
3. Pull catheter gently
4. Remove **entire string loop** Good practice ✅

   → do NOT leave foreign body

Risk if drain is pulled out without unlocking:

- Pulling locked drain → liver / organ laceration



Episode 10: Biopsies - Part 1

🧠 1. Core Concept

🎯 **Purpose of biopsy:**

- Diagnosis → Pathological characterization like benign Vs malignant
- Receptor status → guides systemic therapy
- Genetic profiling → Futher management

🗂️ 2. Classification of Biopsies

🏥 A. Excisional Biopsy (Surgical)

Feature	Details
Definition	Entire mass removed, usually surgically
Advantage	Full tissue → best diagnostic yield
Limitation	Invasive, not always feasible

💡 **Key Insight**

- Maximum information → excisional Biopsy
- Poor accessibility / staging needed → Core Biopsy

🩻 B. Percutaneous Biopsy (IR Standard)

Type	What you get	Main use
FNAC	Cells only	Thyroid, lymph nodes
Core biopsy	Soft tissue sample	Oncology standard
Bone biopsy	Bone tissue	Characterization of Bone tumors

🧪 3. FNAC (Fine Needle Aspiration Cytology)

✅ Indications

- Thyroid nodules
- Lymph nodes

🧭 Technique (Stepwise)

1. Local anesthesia → lidocaine
2. Insert needle (22–25G) + stylet
3. Remove stylet
4. Attach syringe → apply suction
5. Move needle in and out inside the lesion
6. Collect sample → smear on slide

⚖️ Pros vs Cons

Pros	Cons
Simple	No tissue for evaluation
Low risk	Limited information
Minimal trauma/ bleeding	Limited yield for advanced studies

🥇 4. Core Biopsy (Gold Standard)

🧩 Concept

- Provides tisse sample→ preserves architecture

⚙️ Mechanism

Step	Action
1. Coring	Inner needle captures tissue (notch)
2. Cutting	Outer cuting needle shaves off the tissue

➡️ Flow

- Needle enters → notch fills → outer neelde cuts → core obtained

🧰 5. Core Biopsy Needle Systems

🟦 A. Semi-Automated System

⚙️ Mechanism

- Advance inner needle manually
- Fire outer cutting neelde by releasing a spring

🧾 Key Features

Feature	Description
Control	High
Throw length	Usually 1 cm or 2 cm
Dead space	~0.5 cm (no sampling)
Safety	Cutting needle does NOT go beyond tip

✅ Advantages / Disadvantages

Advantages	Disadvantages
High precision	Tissue sample may be fragmented
Safer near vessels	Hard/ Fibrotic may be hard to penetrate

🎯 Best Indications

- Near vessels
- Near critical organs

> 🧠 **Clinical Logic**
>
> - Critical anatomy nearby → **Semi-automated = safest**

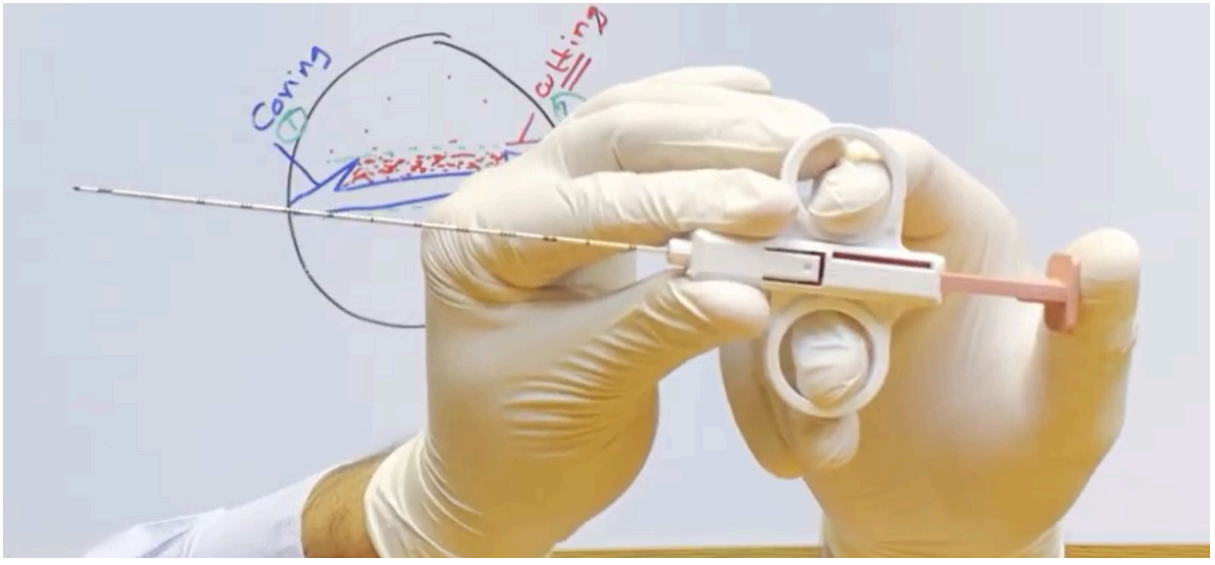

🟥 B. Fully Automated System

⚡ Mechanism

- Single trigger → coring + cutting instantly

🧾 Key Features

Feature	Description
Speed	Very fast
Throw length	13 / 23 / 33 mm (depending on the needle type)
Safety lock	Green = ready, Red = locked

⚖️ Advantages / Disadvantages

Advantages	Disadvantages
Strong penetration	Less control
Better tissue sample	Risk of overshooting

🎯 Best Indications

- Hard lesions
- Fibrotic masses
- Mobile lesions (e.g., breast)

> 🧠 **Clinical Logic**
>
> - Hard / mobile lesion → **Fully automated = better**

📏 Distance Calculation

- Fully automated needle → Fires very quickly so needs accurate shooting distance estimation

📌 **Rule**

- Measure lesion depth using imaging
- Match with appropriate throw

Risk

- Excess throw (overshooting) → vessel / organ injury

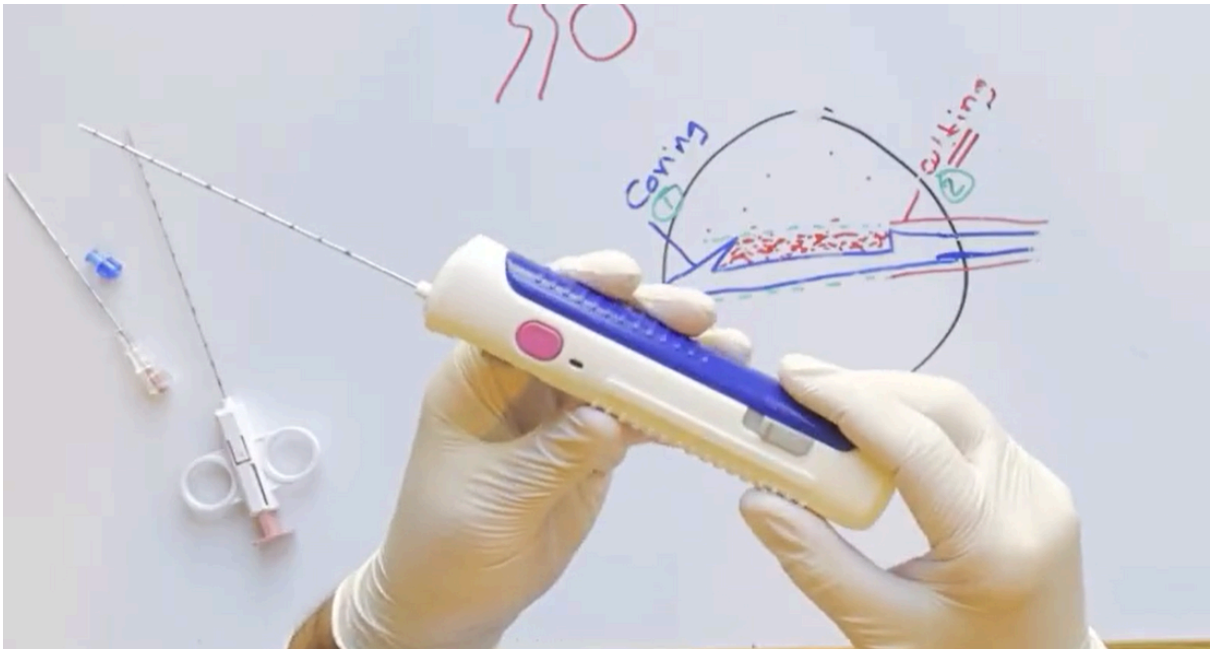

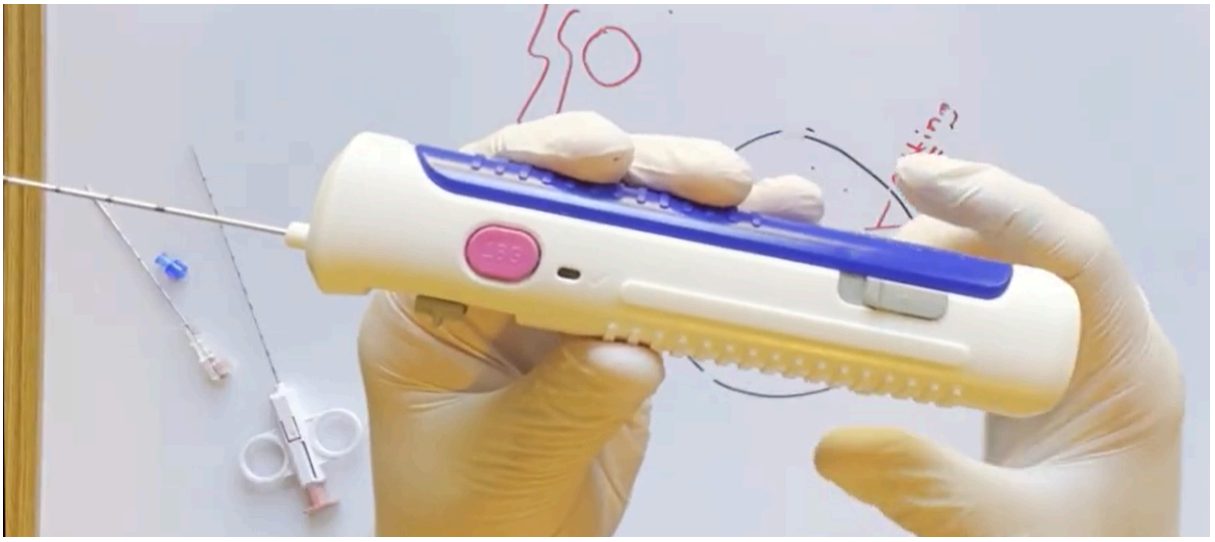



Episode 11: Biopsies - Part 2

> 🎯 **Goal:** Practical, safe biopsy technique (single-stick vs coaxial) + bone biopsy pearls.

1) Basic biopsy workflow 🧩

1. **Plan**
   - Identify lesion → plan the **safest path**
2. **Anesthetize**
   - Local anesthesia: **lidocaine**
3. **Access**
   - Small **skin nick/incision** → easier needle entry
4. **Target**
   - Advance needle under imaging guidance (**US / CT**)
5. **Sample**
   - Obtain tissue cores
6. **Finish**

- Remove needle → send specimen to **pathology**

---

2) Single-stick technique (repeated passes) 🪡

Definition: Needle enters lesion → take sample → remove entire needle → re-enter for another sample.

Steps

- Insert biopsy needle directly
- Advance into lesion
- Extend coring needle
- Fire / release spring
- Remove needle
- Retrieve specimen

Best used for ✅

- Superficial lesions
- Low bleeding-risk lesions

Main drawback ⚠️

- Every new pass = new tissue trauma
- Higher bleeding risk with multiple passes

---

3) Coaxial technique (preferred for deep targets) 🎯

Definition: Outer coaxial needle stays in place → multiple biopsies through the same tract.

Why it's better

- One capsular puncture only
- Less pain
- Less bleeding
- Ideal for deep organs (liver, kidney, deep abdominal lesions)

---

4) Coaxial technique — step-by-step 🧭

1. **Anesthetize**
   - Lidocaine → skin + deeper tissues + organ capsule
2. **Skin nick**
   - Small incision for easier needle entry
3. **Insert coaxial needle**
   - Advance under **US/CT guidance** until lesion is reached
4. **Remove inner stylet**
   - Leave outer coaxial needle in place
5. **Insert biopsy needle**
   - Pass biopsy gun/needle through coaxial needle
6. **Position coring needle notch**
   - Ensure notch is inside target lesion
7. **Fire**
   - Obtain tissue core
8. **Remove biopsy needle**
   - Keep coaxial needle in place
9. **Retrieve the sample**
10. **Repeat as needed**
    - Take multiple cores through same tract
11. **Remove coaxial needle**

- After adequate samples are obtained

---

5) Key advantage of coaxial technique ⭐

You can take **2–4+ samples** without:

- Re-puncturing capsule
- Increasing bleeding risk

Rule: Less trauma = fewer complications.

---

6) Coaxial “pearl” (common mistake) 💡

⚠️ **Issue:** Inner stylet protrude **~0.5 cm beyond outer needle**.

Why it matters

If the outer needle stops exactly at lesion edge:

- After removing stylet → blunt outer needle may sit **outside lesion**
- Then: cannot penetrate lesion properly

Solution

Advance at least **0.5 cm inside lesion** before removing the stylet.

---

7) Confirm the coaxial needle lock 🔒

Before insertion:

- Ensure the coaxial system is **fully locked at the hub**

If not:

- Stylet may move backwards unexpectedly
- Difficult entry
- Loss of control

Always double-check even if a technician prepared it.

---

8) Maintain coaxial needle position (high-yield) 🧷

While inserting/removing the biopsy needle:

- Hold coaxial needle **steady**
- Watch external markers constantly

If coaxial needle moves:

- Can go deeper than intended / overshoot lesion
- May injure vessels

---

9) Before firing biopsy gun ✅

Always confirm:

- Needle tip location
- Lesion position
- Safe trajectory

Use **Ultrasound / CT confirmation** before firing.

---

10) Number of samples 🧪

Common practice → **3 cores**

- 1st may be inadequate
- 2nd usually diagnostic
- 3rd confirms adequacy

---

11) Semi-automated vs fully automated biopsy needle ⚙️

Feature	Semi-Automated Needle	Fully Automated Needle
Mechanism	Inner coring needle advanced manually → then fired	Both corring needle + cutting cannula fire automatically

Feature	Semi-Automated Needle	Fully Automated Needle
Operator control	Higher	Lower
Speed	Slower	Faster
Risk of overshooting lesion	Lower	Higher
Sample quality	Good	Better
Best use	Lesions requiring careful control near critical structures	Easier lesions with safe margins

12) Bone biopsy (different from soft tissue) 🦴

> **Problem:** Bone cortex is very hard → needs larger needles + stronger system + drilling capability.

13) Bone biopsy equipment 🧰

- **Coaxial bone needle:** penetrates cortex
- **Diamond-shaped stylet:**
  - very sharp
  - helps penetrate bone



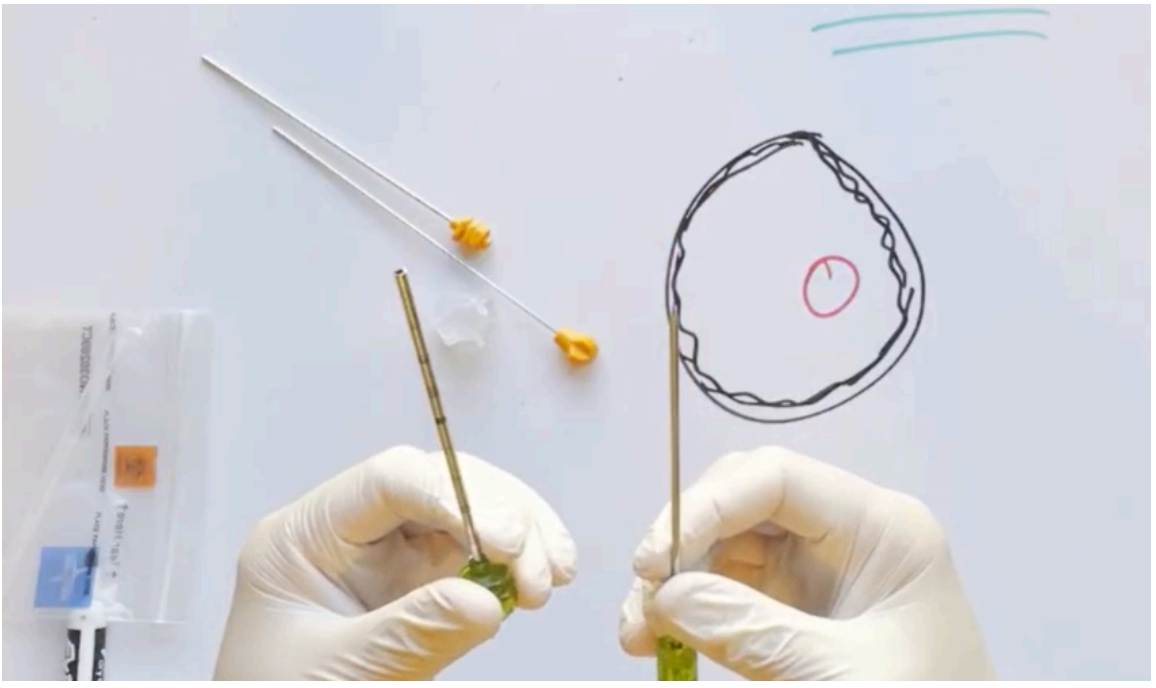

14) Bone access methods 🛠️

- Manual drilling → more control initially
- Electric drill → faster & more powerful

15) Bone biopsy tip ⭐

Initially penetrate at least **0.5 cm**

Why: bone cortex is slippery → prevents needle slipping.

---

16) Bone biopsy sampling mechanism

Unlike soft tissue:

- ❌ No spring-loaded cutting needle

Instead:

- Sharp blades cut tissue
- Sample gets trapped inside needle

Then:

- Use a pusher device → expel sample

---

17) Bone tumor biopsy — coordinate with ortho 🧑‍⚕️

Very important because:

- Future surgery may require sacrificing specific muscles
- Biopsy tract should align with the **future surgical plan**

---

18) Needle tract seeding (rare) ⚠️

- Tumor cells may spread along the biopsy tract
- Rare but real (especially in malignant bone lesions)

---

19) If the surgeon suggests an unsafe approach 🛑

Do **not** blindly follow if the approach crosses:

- Major vessels
- Dangerous anatomy

Discuss alternatives — patient safety first.



Episode 12: Biopsies - Part 3

> 🎯 **Goal:** Practical biopsy tips & tricks that apply *across all biopsy types* — specimen handling, patient prep, depth control, sampling strategy, organ-specific pearls (lung & kidney), sample-length control, and the curved-needle technique.

> 📝 **Note:** This episode covers general principles only. Organ-specific biopsies (lung, liver, kidney, etc.) Will be covered in their dedicated sessions.

🧠 1. Specimen Handling

🔬 Not All Specimens Are the Same

- **Know the clinical suspicion** *before* taking the biopsy — it dictates how the sample must be preserved.
- Most specimens → **formalin** (suitable for routine histopathology).
- Some specimens → require a **different medium**. Exam point ⚠️
  - **Lymphoma** → may need **flow cytometry** to determine the exact subtype.

- ✅ Use a dedicated medium (e.g., **RPMI**) — though the exact medium varies by institution.

⚠️ Why It Matters

- Imagine sampling a *very challenging* lesion → sending the precious sample → lab replies the test **cannot be performed** because it was placed in the **wrong medium**. 🚫

🛠️ What To Do (Communication Pearl) Good practice ✅

- Keep **contact numbers of trusted pathologists** saved on your phone (as discussed in the *First Day IR* episode).
- If the sample will go a specific lab → call them and ask **which medium** they want.
- If that's not possible → contact a **trusted pathologist** to ask the appropriate medium for that sample.

🧴 2. The Formalin Rule (Needle–Formalin Contact)

> 🔁 **Reminder:** We usually collect **3 samples** to ensure adequacy — 1st may be suboptimal, 2nd may be better, 3rd serves as confirmatory.

🚫 The Critical Rule Bad practice 🚫

- The **needle tip must NEVER touch formalin** and then be reinserted into the patient.
- Do **not** wash the specimen out into the formalin cup using the needle, then reuse that same needle.
- ❌ There is **no** "wipe it off and reuse" — this is **not** recommended.

💀 Why?

- Formalin is **highly irritant** → can cause **inflammation**, **infection** and even **tissue necrosis**.

✅ Correct Specimen Transfer Good practice ✅

- Use the tip of a **needle** or a **scalpel blade** to gently transfer the specimen onto the blade → then place into formalin.
- Some biopsy sets include a **small plastic transfer device** designed to move the sample safely.

🗣️ 3. The Clicking Sound

- Core biopsy needles fire with a **clicking sound**.
- ⚠️ **The patient does NOT know this!**
- Sudden click → patient **startles** → unexpected movement → **self-injury** or procedural complication.

✅ How To Prepare the Patient Good practice ✅

- **Talk to the patient before sampling.**
- If the patient can tolerate it → **show the needle** and explain the click.
  - The click is **not painful** — it actually means we're in the **right position** and successfully obtaining the sample.
- If the patient is **afraid of needles** → no need to show it.

> 💡 **Key principle:** Proper patient preparation prevents movement-related complications.

📏 4. Know the depth of the lesion BEFORE you start

- Always know the **depth of the lesion** before starting — using **US** or **CT**.
- Example: lesion measured at **5 cm deep** on CT.

🧭 Depth Control Techniques Good practice ✅

- **Marker method:** advance the marker to **5 cm** before insertion → needle stops at the 5 cm mark.
- **Scale method:** if no marker → use the printed scale on the needle (1, 2, 3, 4, 5) → grip the needle at **5 cm** → insert → your hand naturally stops you at 5

cm.

🚫 The Danger: Overshooting Bad practice 🚫

- When the needle **can't be seen clearly**, there's a constant tendency to **push further** ("we haven't reached it yet").
- Real-world example: lesion at **5 cm**, but the needle has already advanced to **9 cm**. ⚠️
- ➡️ **If you reach 5 cm and still can't visualize the needle → STOP and re-evaluate.** Most likely something is wrong.

> 🔑 Good orientation about lesion depth **from the very beginning** is essential — especially for residents in early training.

🩸 5. Why the First & Second Samples Are Best

> 📌 **Rule:** Your best chance of a good sample is the **1st or 2nd attempt**. After the 2nd, quality starts to decrease.

🫁 Example 1 — Lung (Highly Vascular)

- Lung tissue is **highly vascular** → bleeds easily.
- 1st sample → some bleeding.
- 2nd sample → bleeding increases.
- 3rd attempt → bleeding may obscure the original lesion entirely. ❌



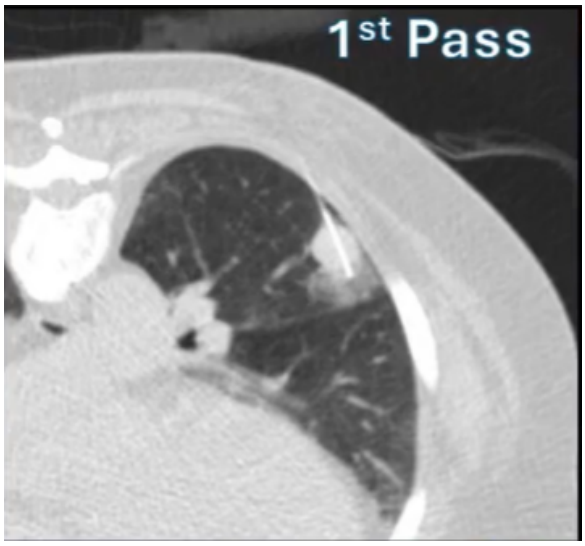

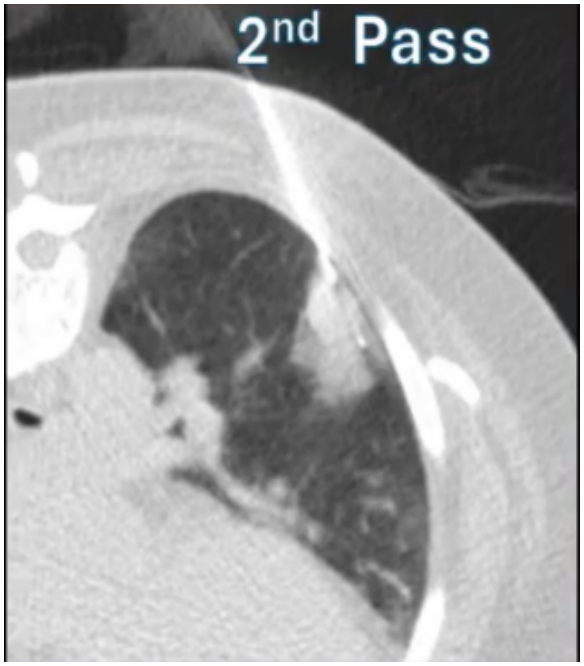

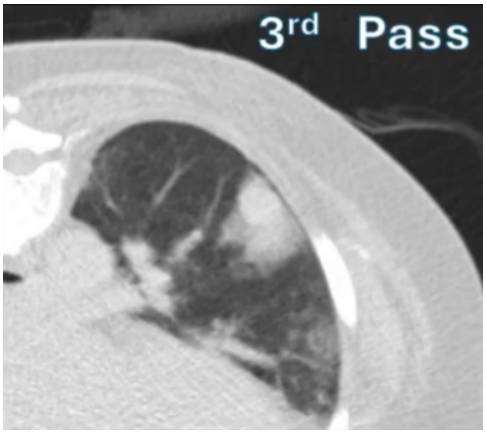

🫀 Example 2 — Liver (Air Introduction)

- Coaxial workflow: each pass → remove inner stylet → insert biopsy needle → **air is introduced**.
- Air → **echogenicity** appears within the lesion → increasing echogenicity → harder visualization under US guidance.

> 💡 **Key point:** Don't rush. Beginners feel the need to sample quickly — instead, **take your time** on the 1st & 2nd samples.

📐 6. Needle Size (Gauge)

- Biopsy needles are measured in **gauge (G)**: e.g., 14G, 16G, 18G, 20G.
- 🔁 **Higher gauge = smaller needle.**

Needle	Sample Size	Bleeding Risk
16 G	Larger sample	↑ Higher bleeding
18 G ✅	Balanced (most common)	Moderate
20 G	Smaller sample	↓ Lower bleeding

- **18 G** = best balance of adequate sample vs. minimal trauma → most commonly used.
- **Lung biopsy:** some prefer **20 G** (lung bleeds easily); others choose **18 G** for better sample (accepting ↑ bleeding).

> ⚖️ Ultimately depends on your **institution and protocol**.

🎯 7. Which Part of the Lesion to Sample

🧬 Tumor Biology

- A neoplastic mass starts small → grows outward → develops **peripheral neovascularization**.
- Edges → rich blood supply | Center → poor supply → **central necrosis**.

❌ Avoid the Necrotic Center

- Central necrotic sampling → report: *"Necrotic tissue, not enough to make a diagnosis."* 🚫
- **Trap for beginners (US guidance):** the necrotic center is fluid-like → **hypoechoic** → easy to confirm the echogenic needle is "on target." But it is **NOT** the best sampling site.

✅ Target the Periphery Good practice ✅

- The **periphery** is the more appropriate target — not the center/deep center.
- On **PET-CT** → the periphery is usually the **'hot' area** → confirms it's the better biopsy target.
- On **CT with contrast** → target the **enhancing part**.

> 🔑 **Always review previous imaging** before biopsy → identify best site, optimal approach, depth, and needle length.

📋 Guide Your Technician on Needle Length

- Lesion **6 cm deep** → a **10 cm** coaxial needle is sufficient (leaves 2–3 cm margin).
- Lesion **15 cm deep** → a 10 cm coaxial needle is **NOT enough** → withdraw and switch to a longer needle.
- ➡️ Plan all of this **in advance**.

💧 8. Surprise Fluid — Don't Discard It! Good practice ✅

- Scenario: you advance the coaxial needle into the lesion → withdraw inner stylet → **fluid comes out**.
- ✅ Recommended approach:
  - Connect the coaxial needle to a **syringe** → aspirate the fluid (**~5 cc**).
  - Send for **cytology** → may be sufficient to identify the cancer type.
- While there → slightly adjust position (up, down, side to side) → sample multiple areas → ↑ diagnostic yield.

> ⚠️ **Expect surprises.** If you hit fluid → **aspirate and send for cytology** → **don't discard it.**

🫁 9. Special Organ: Lung — Preventing Pneumothorax

The Problem

- Peripheral lung lesion → after sampling, the needle tip may shift into the **pleural space** instead of staying in the lung.
- If you remove the inner stylet without realizing → **very high pneumothorax risk**.
- Patient breathes → **negative pressure** in pleural space → air enters → **pneumothorax**. 🚫
- ⚠️ This often happens while you're **inspecting the sample** with the needle left **open**.

🛡️ How To Prevent It — The Saline Seal Good practice ✅

1. Before withdrawing the stylet, ensure a **good seal**.
2. An experienced technician keeps a **saline syringe** ready.
3. As you withdraw the stylet → assistant places **a few drops of saline** on the needle tip.
4. The saline drop acts like a **valve** → prevents air entry.
5. After withdrawing → **reinsert the stylet halfway** into the coaxial needle → seals the tract.
6. For the next sample → remove the stylet → immediately **place your finger over the hub** → reinsert needle → sample.
7. Repeat the **saline + finger + halfway-stylet** sequence each time.

> 💡 Simple steps, but they make a **significant difference**.

🫘 10. Special Organ: Kidney — Managing Bleeding

Why the Kidney Bleeds

- Receives **20–25% of cardiac output** (~1 liter/min) → **highly vascular**.
- Bleeding during kidney biopsy is **common and expected**.

> ⚠️ **Advice:** If you've never done a biopsy, **don't start with the kidney** unless supervised — the bleeding can be intimidating.

🩹 Hemostatic Options (in order of availability)

A. Surgiflo (hemostatic gelatin) ✅
- Powder form → mixed into a **gel**.
- Connect syringe to needle → inject **as you withdraw** → gel lines the tract step by step.
- Acts as a **scaffold for platelets** → forms a clot.
- ✅ Stops bleeding immediately | **Temporary** → fully absorbed in **4–6 weeks**.
- ⚠️ **Don't overdo it** — just enough to line the tract. Excess entering the bloodstream → complications. 🚫

B. Gelfoam slurry
- Commonly available alternative if Surgiflo isn't.
- Mixed into a **slurry** → injected. (More detail in the **embolics** episode.)

C. Autologous clot technique (no agents available)
- *Old method:* draw **~5 mL** of the patient's own blood → let it clot → use as hemostatic agent.
- *Applied via the needle:*

1. Insert the stylet and leave it **midway** (**~5 minutes**).
2. Blood enters the needle lumen but is stopped by the plug → **clots within the lumen**.
3. On removal → advance the formed clot inward → withdraw needle → no active bleeding.

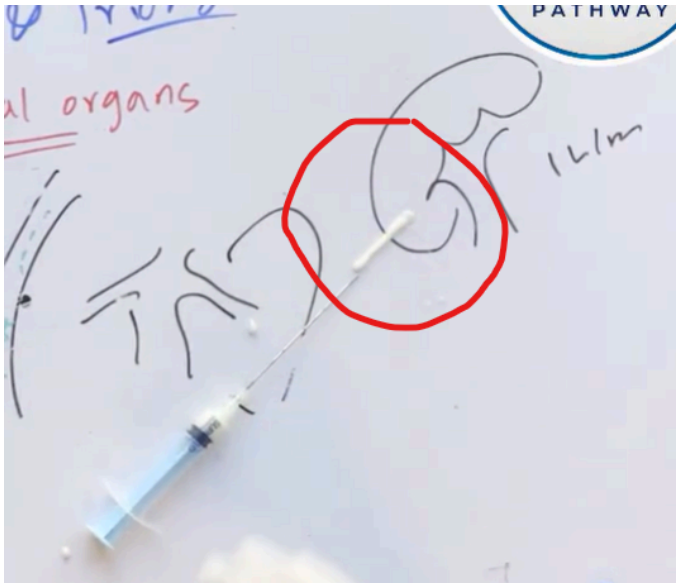

> 🔑 **Universal pearl:** As soon as you withdraw the needle, **insert the stylet halfway and leave it in place.** Many complications occur *after* sampling — when your attention shifts to checking the sample while blood escapes or air enters.

📊 11. 1 cm vs 2 cm Biopsy

- By logic, a **2 cm sample > 1 cm sample** (more tissue).
- **But** limitations apply:
  - Lesion is only **0.9 cm** → you can't take 2 cm.
  - Lesion is **5 cm** → a 2 cm sample is more appropriate.

Why Pathologists Dislike the 1 cm Sample

1. It's **shorter** → less tissue.
2. ⚠️ It tends to be **fragmented** — pathologists prefer **one intact piece**.

> ✅ Aim for at least **2 of 3 samples intact**.

Why Fragmentation Happens

- Related to **sample length** *and* **spring force**.

- **Stronger spring** → better quality, **less fragmentation**.

⚙️ 12. Getting a 1 cm Sample with a 2 cm Spring

> **Question:** Can we obtain a **1 cm biopsy** using a **2 cm needle** with stronger spring tension?
> **Answer:** ✅ **Yes.** (Done manually in the past; now devices allow precise sampling.)

🔵 A. The Spacer Cap Method

> 💡 **Technician note:** *Every component in the set has a purpose.* Don't throw parts away — if you don't know a part's use, **ask** an experienced colleague or the company rep.

- The cap is **1 cm long** → attach it to the hub → adds an extra **1 cm**.
- Set needle to **2 cm** → advance until hubbed against the **blue piece** → you're still **1 cm short** of the original hub.
- Result: that extra 1 cm is **subtracted** from the notch → only **1 cm is exposed** → **1 cm sample** with full **2 cm spring force**.



🆕 B. SuperCore Advantage (Argon)

- Newer version of the older **SuperCore**.
- Same concept, more **ergonomic** design.
- **Built-in length selector:**
  - Pull back **1 click** → **10 mm** (1 cm).
  - Pull back **2 clicks** → **20 mm** (2 cm).
  - The clicks sound different.
- Can set the **2 cm spring** + adjust the part to **1 cm** → strong spring, 1 cm sample.

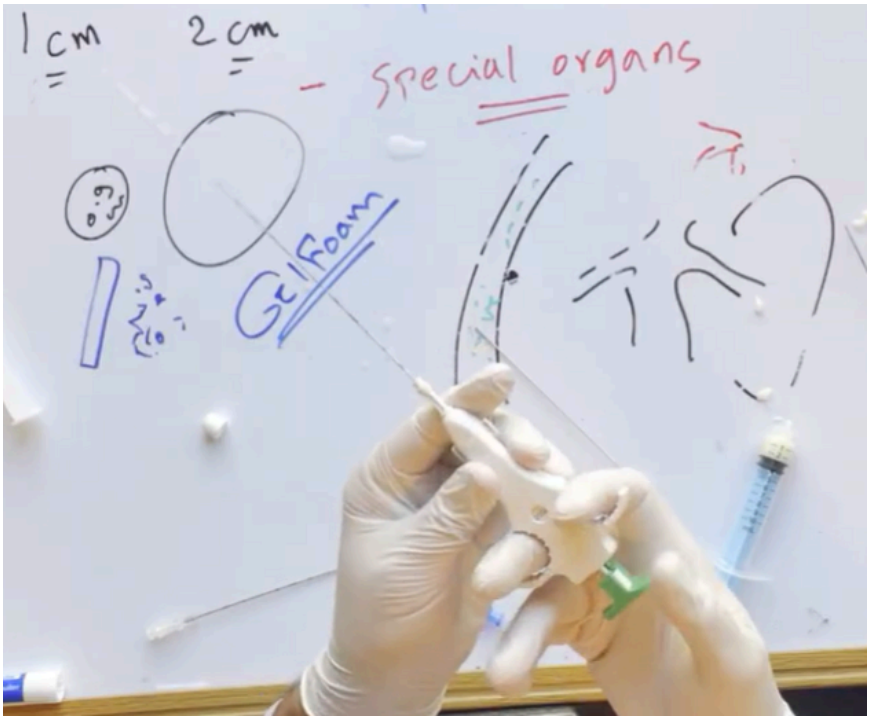

✋ C. Manual Technique (no special device)

- Set needle to **2 cm** → insert through coaxial needle → **stop 1 cm short of the hub** (don't advance fully).
- Maintain the **1 cm gap** → on firing, only **1 cm is exposed** → 1 cm sample with 2 cm spring force.

> ⚠️ **Why this is taught last:** It requires experience. While advancing you may **accidentally lose the 1 cm gap** → you've switched to a 2 cm biopsy.

> ✅ Practice on **superficial, low-risk** cases first, and **always keep your eye on that 1 cm**.

🪝 13. The Curved Needle Technique

> **Scenario:** Lesion with a **highly necrotic center** — a straight trajectory keeps biopsying the necrotic part.

- No matter how many times you advance straight → you re-enter the **same** (necrotic) area.
- **First solution:** redirect the **coaxial needle** slightly up/down to reach other areas.
- **If that's not easy:** use the **curved needle** modification:

🧭 How To Curve It

1. Push the **coring needle** out.
2. Bend it slightly **outward**, about **20–30°**.
3. ✅ The **notch must be on the convex (outer) side** of the curve.
4. ❌ Do **NOT** bend it inward → the spring mechanism likely won't function.
5. ⚠️ Don't **over-bend** beyond the acceptable limit → may **damage the needle mechanism**.



Why Use It

1. Gives the needle **direction** → sample areas right/left/up/down, away from the necrotic center.
2. Some argue curved-needle samples are **higher quality** than straight ones (still **debated**).



Episode 13: IR Training in the USA - Part 1

> 🎯 **Goal:** A simple map of the **traditional pathways** to IR training in the USA — for medical students, interns, residents, and fellows (USMGs & IMGs alike).

> 📝 **Note:** Recorded in **2026**. If you're watching later (e.g., 2028 or 2030) → **double-check** the info, since rules may have changed. This is the **general framework**: exceptions exist.

🏛️ 1. Get Your Info From the Right Sources

- Don't rely on friends, relatives, or even the channel for **your specific case** → ask the official bodies.
- Describe your situation **accurately and in detail** → their opinion outweighs any other source.

Body	Role
ACGME (Accreditation Council for Graduate Medical Education)	Accredits training programs (residency & fellowship) → makes sure programs meet standards & training quality is high

Body	Role
ABR (American Board of Radiology)	Board certification → verifies your training + runs the board exams → certification lets you practice radiology in the US

🗂️ 2. Two Big Categories

- **Traditional pathways** → the routes any graduate follows: **USMGs** (graduated in the US) or **IMGs** (International Medical Graduates).
- **Non-traditional pathways** → covered in **Part 2** (Alternate pathway, etc.).

📅 3. Why 2020 Matters — Old vs New System

🕰️ Before 2020

- **Preliminary year** (internship) → **4 years DR** → **1-year fellowship** (Neuro, Body, IR...) → ABR exams → **board certified**.

🔄 What Changed

- IR expanded a lot → **one year of IR training was no longer enough**.
- Need for **more clinical training** + still keep **strong DR training**.

> 💡 **Key principle:** To be a good interventional radiologist, you must first be a **good diagnostic radiologist**.

- ➡️ Starting **July 2020** → the **Integrated IR/DR Residency** was introduced.

🏅 4. Pathway 1 — Integrated IR/DR Residency

- Now the **main** residency track for IR training.
- **Prelim year** → **3 years DR** → **2 years IR** = **6 years total**.

🩺 The Preliminary Year

- Three types in the US:
  - **Medicine prelim** → focused on internal medicine.

    - **Surgery prelim** → focused on surgery.
    - **Transitional Year** → mix of medicine, surgery & electives (most similar to internship abroad) → makes you competent as a clinician.
- DR & IR are **"advanced training"** in the US → you **must** finish a prelim year before starting.
- The prelim year is **as important as the radiology spot** itself → without it, you're **not qualified** to start.
- In the Match you apply to **two things**: the **radiology program** + a **prelim year** position.
- Prelim years are **competitive** (needed by IR, DR and many other specialties).
- You can match a prelim in one state (e.g., **New York**) and radiology in a totally different state (e.g., **California**).

📦 Categorical Programs

- Programs that include the **prelim year in the package** with the radiology training.
- ✅ Advantages:
    - **Guaranteed** prelim year → no separate prelim match.
    - Prelim at the **same institution** → no moving between states (can be overwhelming).
- ⚠️ Excellent but **limited in number**.

🛠️ Match Pearl

- If there's a categorical program → **apply to it**.
- If not → whenever you get a radiology interview at Program A → **also apply to Program A's prelim** (IM or surgery).
    - Reason: **unofficial internal agreements** → radiology may ask IM/surgery to "rank this candidate high."
    - If you really like the program → tell them you **applied to their prelim** too → some may try to help, others can't.

- Matching a prelim somewhere else is **completely fine** → that's what most people do.

🩻 The 3 DR Years

- Mainly diagnostic radiology, with **limited IR exposure** (**~3 IR rotations**).
- Goal isn't to make you an IR yet → just to **know the team & workflow** so you're ready later.

> 🔑 **Focus on DR during these 3 years.** Skills you miss here are hard to catch up on during the final 2 IR-only years.

🔧 The 2 IR Years

- Mostly **IR rotations** + **1-month ICU** rotation (clinical component).
- Any unmet DR requirements → the program may give you time to finish them **before exams & graduation**.

🔀 5. Pathway 2 — ESIR Track (Early Specialization in IR)

> **Scenario:** You didn't match Integrated IR/DR but matched **DR**. Can you still do IR? ✅ **Yes.**

- **Prelim year** → **4 years DR** (4th year modified to be **mostly IR**).
- Talk to the **program director early** → express your interest in IR → curriculum gets restructured.
- Requirements before graduation:
  - **12 IR rotations**
  - **500 procedures**
- If met → eligible for just **1 year** of dedicated IR training (**Independent Residency**).
- That 1-year spot may be at the **same institution** or require a **separate Match** elsewhere → spots are competitive but **available**.

- Total: **6 years** (same as Integrated).

⚠️ Program Must Have an ESIR Track

- ESIR is **not as widely available** as Integrated → and some programs are **cutting it**.
- Check the program **website** → if not listed, just **ask at the interview**: *"I'm interested in IR — do you have an ESIR track?"*

📖 6. Terminology Trap — Integrated vs Independent

- The word **"fellowship" is no longer used** in IR training → now called **Independent Residency**.

Term	What it is
Integrated Residency	A **complete** training system → you graduate **IR/DR**
Independent Residency	Focused IR training for **1 or 2 years** → think of it as the **old fellowship**

> 💡 Use the **same terminology** as the US system when talking to programs — many people mix these two up.

🕐 7. Pathway 3 — DR Residency → 2-Year Independent IR Residency

> **Scenario:** Matched DR **without an ESIR track**, or became interested in IR **late** in DR training.

- **Prelim year → 4 years DR → 2 years Independent IR Residency** → eligible for IR board certification.
- 2 years (not 1) because no IR-focused year was done during DR.
- ✅ **Advantage:** You **don't lose the chance** to become an IR physician.
- ⚠️ **Disadvantage: 7 years total** → one extra year.

- The IR independent residency has a **separate Match** → same or another institution.

> 💬 One extra year to reach something you've always wanted is **not a big deal** — but still something to consider.

📊 8. Summary of Traditional Pathways

Pathway	Structure	Total
Integrated IR/DR ✅	Prelim + 3 DR + 2 IR	**6 years**
ESIR	Prelim + 4 DR (4th mostly IR) + 1 Independent IR	**6 years**
DR → Independent IR	Prelim + 4 DR + 2 Independent IR	**7 years**

💡 9. Insights & Tips

🔥 Integrated IR/DR Is Very Competitive

- Very competitive **even for US grads** — not just IMGs.
- 2026 numbers: ~**240** Integrated IR/DR slots across the US vs ~**690** applicants.
- IMGs were ~**8–9%** of those who matched → IMGs **still match**, but it's tough.
- Applicants are truly **outstanding** → don't be crushed if you don't match.

🎯 Apply to Both

- Apply to **Integrated IR/DR + DR** at the same time (advice given even to US grads).
  - Match DR **with ESIR** → IR in the **same number of years**.
  - Worst case: DR **without ESIR** → IR with just **1 extra year**.
- You can also reapply to Integrated the following year.

🏅 All Pathways End in IR/DR Certification

- Lets you practice **IR only**, **DR only**, or a **mix** (e.g., 50/50, 30/70).

- As of 2026, the job market is **very good** for both DR and IR.

> ➡️ **Next (Part 2):** Non-traditional pathways — the **Alternate Pathway** and more.



Episode 14: IR Training in the USA - Part 2

> 🎯 **Goal:** The **non-traditional pathways** to IR training in the USA — the IR/DR IMG Alternate Pathway, the 2-Year IMG Alternate Pathway, training without board certification — plus licensing vs certification and how to plan.

> 📝 **Note:** Exact requirements live on the **ABR website** → always check there for your specific case.

🌍 1. The Alternate Pathway — Why It Exists

- The US, like many countries, has a **physician shortage**.
- Idea: physicians **already qualified** in their home country may practice in the US under certain conditions after the system confirms they have the **skills & training** to practice safely.
- Official name: **IR/DR IMG Alternate Pathway**
  - Commonly called just **"the alternate pathway"** → use the official name when contacting institutions.

📋 2. Requirements

🎓 Training in Your Home Country (outside US & Canada)

- **≥1 year** of prelim / clinical training (usually the **internship year**).
- **≥3 years** of **DR** training (3 is the minimum; **4 is preferable**).
- **≥1 year** of **IR** training.
- ✅ **Documentation** of everything → official, properly verified certificates.

🪪 Eligible to Practice Independently at Home

- Proof you're authorized to practice **independently** based on your training, e.g.:
  - A **board certification / fellowship** in your country.
  - **EBIR** (well recognized in the Middle East now).
  - India → **MD** or **MBBS + DNB**.

📝 ECFMG & USMLE

- Must be **ECFMG certified** → **Step 1 + Step 2** required.
- **Step 3** → not required for certification, but **strongly recommended** when applying.
  - Officially required **≥6 months before** applying for the certifying exam.
  - Most programs **prefer** you already have Step 3 when you apply.
  - Also matters for some **visa types**, **billing**, etc.

🪜 3. Steps

1. **Contact programs** you're interested in → introduce yourself → say you're interested in the **IMG alternate pathway** → share your certificates.
2. Program reviews your credentials → **interview**.
3. If you're a good fit → you sign the **SDA (Sponsoring Department Agreement)** → agreement between you & the program, under **ABR** supervision.

4. Training package submitted to the **ABR** → reviews training & documents → **green light** to start.

📦 What the SDA Includes

- **5 years** of training at an institution with **ACGME-accredited IR training**.
  - Not all US programs have ACGME accreditation → the alternate pathway **must** be done at one that does.
- The 5 years can combine: **residency** (up to **4 years**, not more), **fellowships**, and **junior faculty** time.
- Exact distribution → depends on your **agreement** with the program.

Example Common Package	Duration
Independent IR/DR residency (≈ old fellowship)	2 years
Additional fellowships (e.g., MSK, Body)	2 years
Instructor / junior faculty	1 year

⚖️ 4. Pros & Cons

- ✅ Excellent pathway for physicians who **finished (or are finishing)** training at home and want to practice in the US.
- ⚠️ **Time:** ~4–5 years at home + **another 5 years** in the US.

> 💡 That's why starting the **Integrated Residency early** saves time. But if plans changed later → no problem, this pathway is still **very popular**.

🆕 5. Recent Changes That Made It Easier

🏥 More IR Slots

- In the past → entering the alternate pathway was possible, but finding an **IR slot** was very hard.
- Now → IR training is **more widely available**.

🔁 Transfers Allowed

- Before → all **5 years at one institution** → if the program couldn't continue with you (even after 3 years) → you became **ineligible**. 🚫
- Now → transfer allowed across **up to 2 institutions** (e.g., 3–4 years at A → finish at B).
- Still recommended to finish at the **same institution** if possible. Transfer rules → on the **ABR** website.

🔬 Research Can Count

- Up to **12 months** (1 year) of research can count toward the pathway.
- Conditions:
  - Must be done at **institution A or B** (those included in your **SDA**) → research at institution C **won't count**.
  - The **ABR** reviews it and decides if it qualifies → research related to **DR / IR** is more likely to be accepted.
- ✅ Big advantage → can **replace an extra fellowship year** → your previous research isn't wasted.

🔄 6. The 2-Year IMG Alternate Pathway

- 📝 Side note: there's also a separate **DR Alternate Pathway** for those who want **diagnostic radiology only** (details on the ABR website).

When Is It Used?

- A program likes you but has **no ACGME-accredited IR training**.
- Or it has accredited IR training but the slots are **filled by internal candidates**.
- Or you were initially into **DR** and later became interested in **IR**.

How It Works

- Complete the **DR Alternate Pathway** → become **DR certified**.

- Reach out to an institution with **ACGME-accredited IR training** → do **2 years** of training (Independent pathway).
- ➡️ Become **IR/DR certified**.
- The system may also allow **1 year** of independent training instead of 2 (e.g., 1 fellowship-like year + 1 instructor year) → depends on your agreement with the institution.

> ✅ A valuable option for anyone who **missed** the IR/DR alternate pathway and did the DR alternate pathway instead.

🎒 7. IR Training WITHOUT Board Certification

- For people who do NOT **plan to practice in the US** (e.g., want to return home for family/financial reasons).
- ⚠️ Does **NOT** give you the right to practice in the US → **not board eligible**, can't sit for the board exams. Training only.
- Contact programs and state **clearly in all correspondence** that you want **training only**, not board certification.
- Program may be **ACGME-accredited or non-accredited** → doesn't matter much for you.

❌ Misconception: Non-ACGME = Bad Program

- Not true → many non-accredited programs are **excellent**.
- Some institutions choose not to pursue accreditation (complex process) or are still **working toward it**.
- It just means the training **won't make you board eligible**.

What You Get

- A **Certificate of Completion** → confirms 1 or 2 years of training at that institution.

Acceptance Depends on Circumstances

- Requires lots of **communication** with the program.
- Example: 5 slots with only 1 filled → likely to invite you. 4 of 5 filled and talking to others → may not guarantee a spot.
- Program will ask for **all documents** and may seek advice from the **ABR** or another relevant body as needed.

🪪 8. License ≠ Board Certification

	What it means
Board certification (ABR)	Your training is verified + you passed the exams → tells the public your expertise was evaluated & verified
Full unrestricted license	Legal authorization to practice medicine **in a specific state** → each state sets its own requirements

🗒️ ACGME Years & State Licensing

- Alternate pathway needs **≥2 years** of ACGME-accredited training (the IR training).
- The other years (fellowships) can be ACGME or **non-ACGME** accredited.
- But **licensing varies by state**: some require **2 years** of ACGME-accredited training, others **3 years**.
- Example: you want to live in **state A** (family there) and it requires **3 years** → with only 2 you're **not eligible** there (but may be in states B, C, D).
- If you're **flexible** about where you live → 2 accredited years + non-ACGME years + faculty year can be enough.

> 🔑 **Know your target state's licensing requirements** and raise them with the program **up front** (e.g., *"I need 3 years of accredited training"*). If they can only offer 2 → rethink, or find another program.

🧭 9. Guidance — How To Navigate All This

1. **First choice: Integrated IR/DR residency** → most direct route to IR/DR certification. Start **early** (medical school / internship).
2. **Apply to DR at the same time** → if you match DR, you still have **ESIR** or **DR → Independent residency.** You haven't lost the chance — you just adjusted the plan.
3. If that doesn't work either → **don't give up**. Ask yourself if you truly have the passion for IR.
    - If yes → do your radiology residency **at home**, work hard, be a **good resident**, do **research**, go to **conferences** → build a **network** → apply through the **alternate pathways** after residency.

> 💡 There's **more than one pathway** → if one fails, the whole plan hasn't failed. It's competitive for **everyone**, not just IMGs.

🧘 Final Advice

- **Be flexible** → nothing is guaranteed, in or outside the US.
- *"If you can't achieve everything, don't give up on what you can achieve."* → the alternative pathway may even end up being a **better position**.
- **Priorities change** → what matters most now may differ in 5 years.
- **Discuss plans with your family** → these are long-term commitments that take time and effort.



Episode 15: Needles & Guidewires - Part 1

> 🎯 **Goal:** Open the IR toolbox → needles (gauge, color codes, single-wall vs coaxial, Chiba vs trocar, EchoTip) and guidewires (structure, shear off, classifications)

> 📝 **Note:** IR tools fall into **3 categories**: **needles**, **guidewires**, and **catheters**. Catheters will be covered in upcoming episodes.

📐 1. Needle Gauge — Quick Recap

- Needles are measured in **gauge (G)** → works **in reverse**.
- 🔁 **Higher gauge = smaller needle** (21 G is smaller than 18 G).

Needle	Wire it takes
18 G	**0.035"** wire
21 G	**0.018"** wire

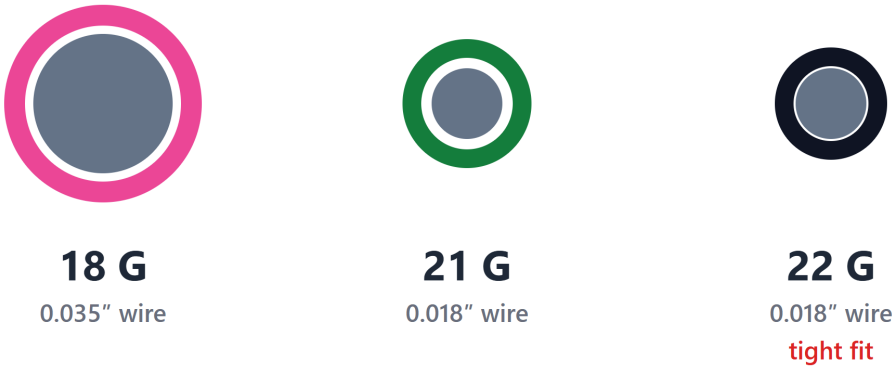

Higher gauge = smaller needle

🎨 Color Coding

- Needles are **color-coded** → easy to identify on a crowded table.

Gauge	Color
18 G	Pink
21 G	Deep green
22 G	Black

❓ 2. Smallest Needle for a 0.018" Wire Exam point ⚠️

- A 0.018" wire fits a **21 G** needle **smoothly**.
- It can technically pass through a **22 G** needle → but the fit is **very tight** → hard to pass & withdraw → risk of **shear-off** (see below).

> 📌 **MCQ:** *"What is the smallest needle that can pass a 0.018" wire?"* → **22 G**.

- In practice → we use **21 G** (standard in **micropuncture**, **AccuStick** and **Neff** sets) → wider lumen → easier wire passage & withdrawal.

💉 3. Single-Wall Needles

- Also called **hollow-core** or **cutting-edge** needles.
- Standard needle with a **beveled tip**

- ✅ The preferred needle for **vascular access**.

✨ The Bevel — 2 Benefits

- **Sharp tip** → passes easily through tissue.
  - e.g., femoral access in a patient with **previous groin surgery / catheterization** → **fibrous tissue** → the sharp bevel cuts through it (hence "cutting-edge").
- **Steerable** → the needle moves **opposite** to the bevel direction.
  - Want it to go **down** → bevel **up**.
  - Want it to go **right** → bevel **left**.

🩸 Application in Vascular Access Good practice ✅

- Operators point the bevel **upward** → needle deflects **downward** → toward the target artery.
- Once past the skin, you can't see the bevel → the **hub marker** (dot or line) is your **only reference** for bevel direction.

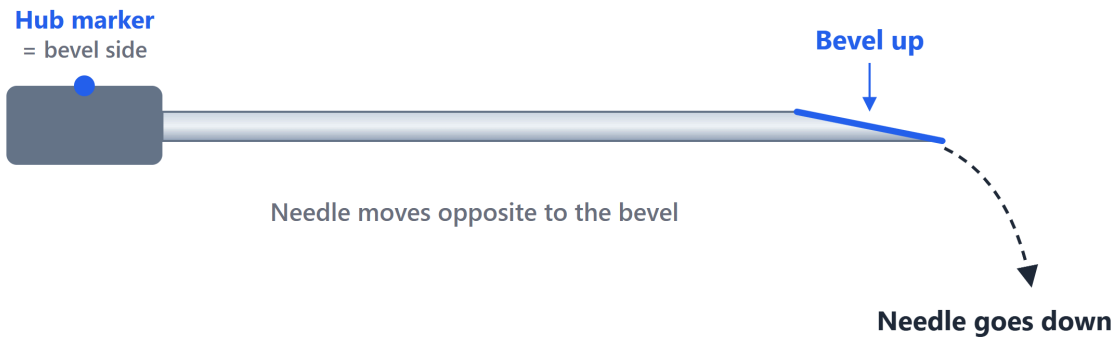

🎯 4. Coaxial Needles

- Same basic needle + an extra component: the **stylet** (a metal piece inside the needle that **locks into the hub**) → one unit.
- Used for **deep organ access** (e.g., **percutaneous nephrostomy**).

Why Use Them?

1. Stylet adds **stiffness** → better control while advancing to a deep organ.
2. Once inside the organ (e.g., the kidney) → **remove the stylet** → needle stays in place with **access maintained** → just advance the wire.

🔍 Chiba vs Trocar — Similar but NOT the Same Exam point ⚠️

	Chiba needle	Trocar needle
Stylet tip	**Beveled** (outer needle & stylet both beveled)	**3-sided diamond-shaped** tip
Direction	**Steerable** (bevel gives direction)	No fixed direction → follows where you guide it
Use	Deep organ access → preferred by many	Deep organ access → per operator preference & availability

- Both are coaxial needles and come in deep-access sets (e.g., **Neff**, **AccuStick**).

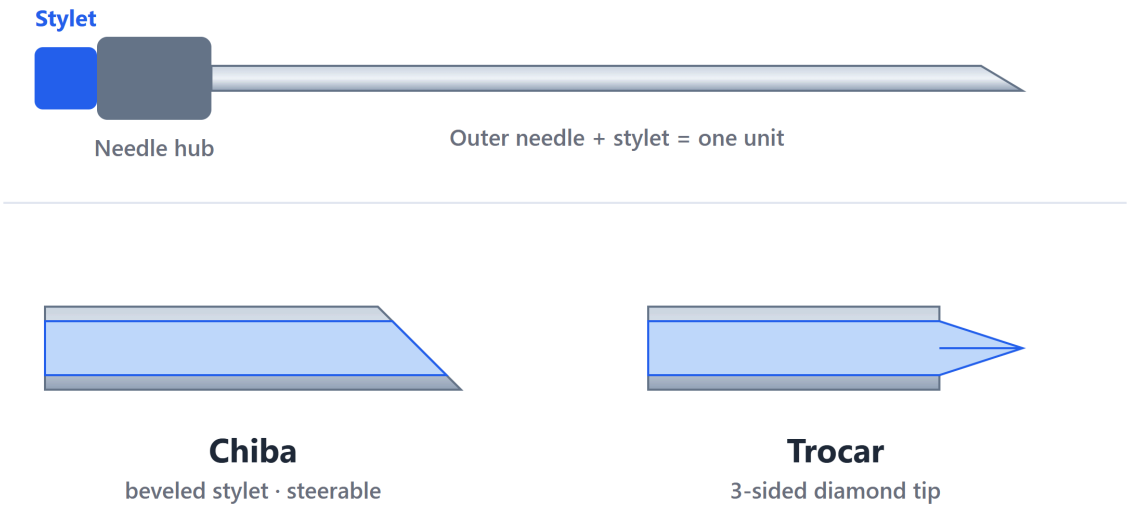

📶 5. EchoTip Needles

- Some needle packages show a **Wi-Fi–like symbol**, sometimes labeled **EchoTip** (the label may be absent).
- Under **CT / fluoroscopy** → no problem → all needles are **radiopaque**.
- Under **ultrasound** → **echogenicity** matters a lot, especially:
  - For **beginners**.
  - In **obese** patients or **deep** organs.
- EchoTip = **tiny irregularities** at the needle tip → ↑ ultrasound **reflectivity** → better tip visualization.
- Some operators make these irregularities **manually** with a scalpel → do it **carefully**.

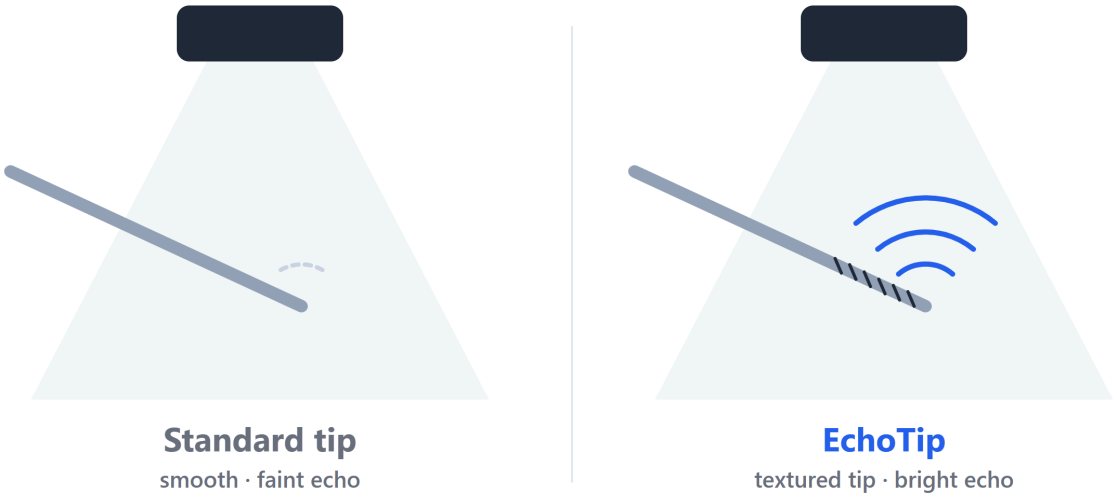

> 💡 Early in training → use an **EchoTip needle** for US-guided access → tip is much easier to see.

🧵 6. Guidewire Structure

- A guidewire is **not just an ordinary wire** (that's why it's expensive!). Cross-section → **3 components**:

1. **Mandrel** → the **central core** → determines most characteristics (**stiff** vs **floppy**). Made of **stainless steel** or **nitinol**.

2. **Coil** → wrapped around the mandrel → key for **selective catheterization**.
3. **Securing** along the whole length → keeps the coil from **unwinding**.

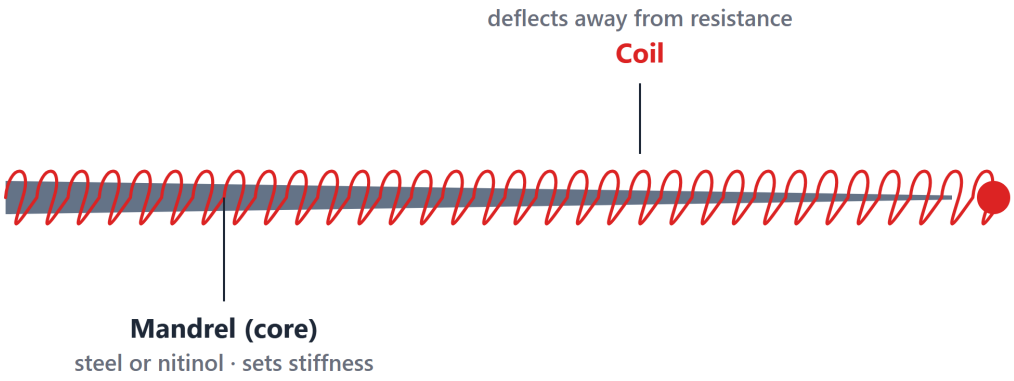

🌀 7. Why the Coil Matters

- A coil that meets **resistance** → **deflects away** from the obstacle.
- ➡️ This is what lets the wire **navigate & select** vessels.

🚫 Just Pushing the Wire Bad practice 🚫

- Pushing straight forward → tip hits the **vessel wall** at a branch and **stops**.
- You **lose the main advantage** of the coil design.

✅ Push + Spin Good practice ✅

- Forward movement should always be combined with **gentle rotation (spinning)** → by hand or with a **torque device**.
- Coil senses resistance → deflects toward the **path of lower resistance** → wire follows the branch.
- Rotation may be **10°, 20°, even 50°** → comes with practice.

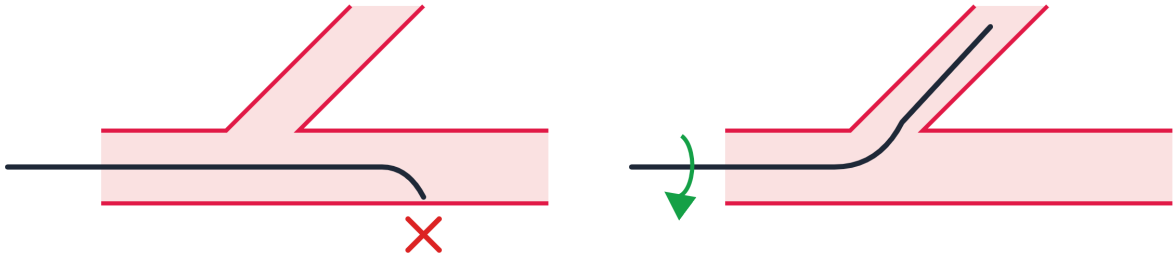

> 💡 The more you practice, the better you feel the **feedback** from your tools → faster, more efficient procedures.

✂️ 8. Wire Shear-Off — A Serious Complication

> ⚠️ More common than you think — especially with **micro wires** during **micropuncture** access.

How It Happens

- We draw wires as **smooth and straight** → in reality they develop **irregularities/kinks**, especially after a **failed access attempt**.
- On withdrawal → the **needle tip catches the outer coil** → you feel **resistance**.
- Natural reaction → **pull harder** → coil distal to the needle **unwinds/stretches** → wire straightens → **snaps**. 🚫
- Fragment travels in the **bloodstream** → a 5–10 second access becomes a **2–3 hour** procedure → may need **vascular surgery** if snaring fails.

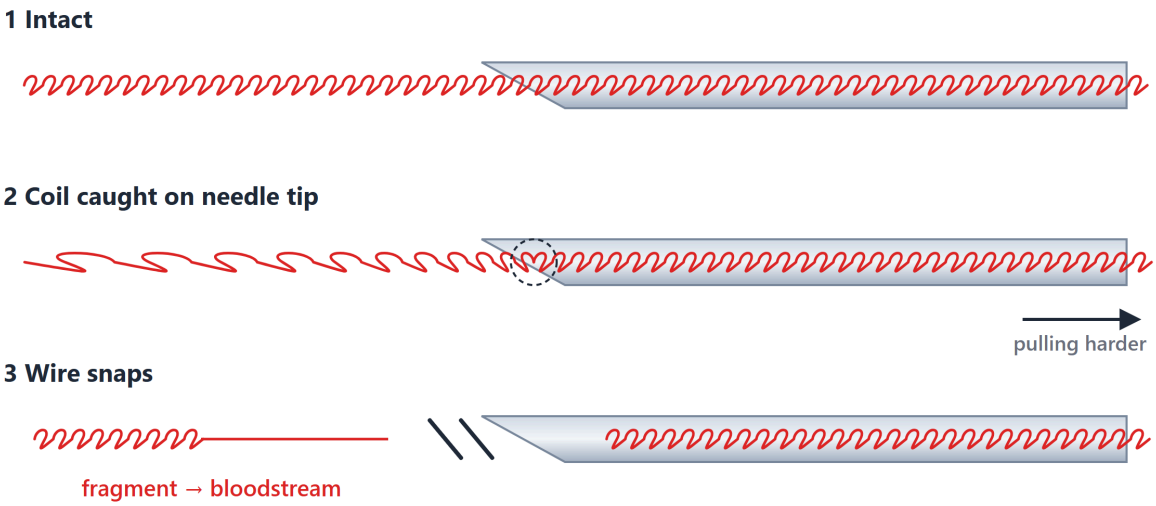

Resistance → check fluoro → remove needle + wire together

🛡️ How To Manage It Good practice ✅

1. Feel **resistance** while advancing or withdrawing → **stop** → check under **fluoroscopy**.
2. You'll likely see the needle angled and the wire **visibly deformed** → this is **not normal**.
3. **Hold needle + wire together** → remove them **as one unit**.
4. Apply **pressure** to the site (1–2, even 3–4 minutes).
5. Re-attempt with a **new needle & new wire**.

> 🔑 Yes, you **lose access** — but that's far easier and safer than leaving a **wire fragment** inside the patient.

🗂️ 9. Guidewire Classification

🔧 A. By Use

Type	Purpose	Features
Access wires	Get into the vessel → switch to another set, place a sheath, etc.	**Short** (e.g., micropuncture wire)
Rail wires	**Exchange** catheters/tools without losing access	**Stable & stiff**
Maneuver wires	**Select** arteries/branches	**Soft** + **angled tip**

- The **angled tip** gives direction → rotate to steer **right or left**. A straight tip has **no direction**.

💧 B. By Coating

- **Hydrophilic coating** → attracts water/fluids → **very slippery when wet**.
  - ✅ Ideal for **selective catheterization** & navigating angles/branches without harm.
  - ⚠️ Becomes **sticky when dry** → keep it **wet** throughout (flush with saline or wipe with **saline-soaked gauze**).
- **Non-hydrophilic** → no coating → used when extra **support** is needed (e.g., straight segments).
  - Doesn't need the same precautions → wetting doesn't change its feel much.
- Example: standard wire through the straight segment → switch to a **hydrophilic** wire to select the branch.

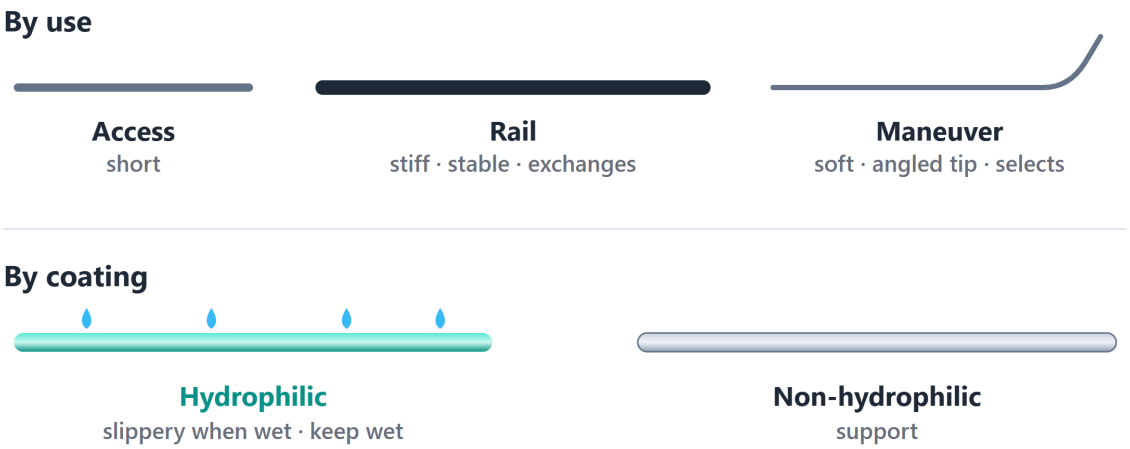

> ➡️ **Next (Part 2):** A more practical classification for training → by **coating + stiffness + Use**.
